

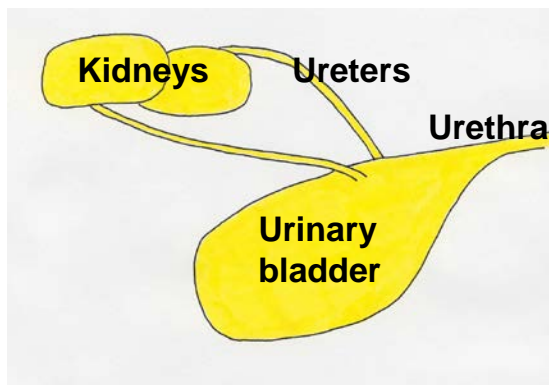
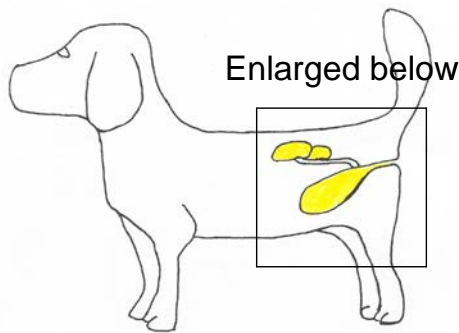
CANINE BLADDER CANCER by Deborah W. Knapp, DVM, Dipl. ACVIM



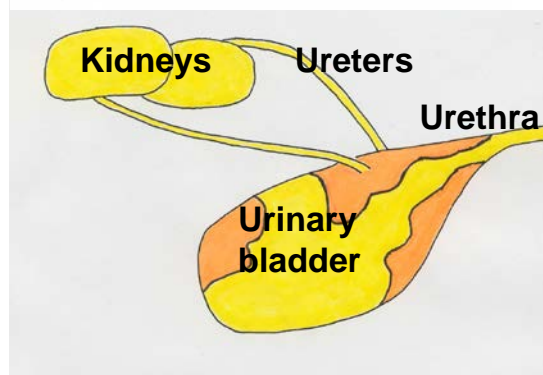
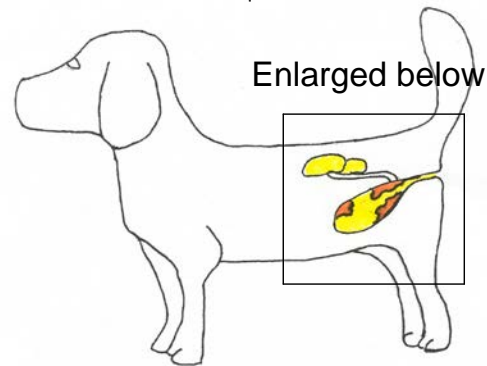
Cancer of the urinary tract in dogs can affect the kidneys, ureters, urinary bladder, prostate, or urethra (see Figure 1). Within the urinary system, the bladder is the location most frequently affected with cancer. Compared to cancer in other locations in the body, bladder cancer is unusual, comprising approximately 2% of all cancers in the dog. With more than 70 million pet dogs in the United States, however, even unusual cancers like bladder cancer, are problems for thousands of dogs and their families.

What is bladder cancer? The most common cancer of the dog urinary bladder is invasive transitional cell carcinoma (TCC) of intermediate to high grade. TCC is also called urothelial carcinoma. TCC is a malignant tumor that develops from the transitional epithelial cells that line the bladder. In dogs, this tumor invades into the deeper layers of the bladder wall including the muscle layers. As the cancer enlarges in the bladder, it can cause obstruction to the flow of urine from the kidneys to the bladder or from the bladder to the outside of the body. Canine TCC also has the ability to spread to lymph nodes and to other organs in the body (lung, liver, others). TCC most frequently is found in the bladder, but can also develop in the kidneys, ureters, prostate, and urethra. In regards to human bladder cancer, most cases fall into two general categories: (1) lower grade, superficial tumors, and (2) higher grade, invasive tumors. It is fortunate that the majority of people with bladder cancer have the lower grade, superficial form of the disease, which typically does not spread beyond the bladder. Dogs, on the other hand, most often develop the higher grade, invasive form of bladder cancer that can grow more quickly and can spread throughout the body.

Normal Female Dog



Female Dog with TCC (see masses in bladder)



What causes TCC in dogs? The exact cause of TCC in an individual dog is usually not known. In general, canine TCC results from a combination of several factors including genetic predisposition and environmental factors. A genetic predisposition is strongly suspected because TCC is more common in specific breeds of dogs. Scottish Terriers have an 18-20 fold higher risk of TCC than other dogs. Shetland Sheepdogs, Beagles, West Highland White Terriers, and Wire Hair Fox Terriers are 3 to 5 times more likely to develop TCC than other dogs. Dogs in related breeds may also have a higher risk of TCC, but this has not been studied yet. Environmental factors identified as risk factors in early studies have included pesticides and insecticides such as "old generation" flea dips. The greatest cause of TCC in humans is smoking. Further study is needed to determine the extent to which second hand smoke could contribute to TCC in dogs.

An association has been found between exposure to lawn herbicides and pesticides and the risk of TCC in Scottish Terriers. Investigators at the Purdue University School of Veterinary Medicine have published a case control study in Scottish Terriers to determine risk factors for the development of TCC. As discussed above, Scottish Terriers have an 18-20 times higher risk for developing TCC than dogs of other breeds. The study was performed to determine if exposure to certain types of environmental chemicals would further increase the risk of TCC in this breed of dog. Environmental exposure histories were compared between 83 Scottish Terriers with TCC (cases) and 83 Scottish Terriers of approximately the same age with other health-related conditions (controls). A significantly increased risk of TCC was found for dogs exposed to lawns or gardens treated with herbicides and insecticides or herbicides alone. In fact dogs exposed to treated lawns were seven times more likely to develop TCC. These findings indicate that Scottish Terriers, as well as other dogs of high-risk breeds for TCC, should be restricted from lawns treated with herbicides and pesticides. The risk of lawn chemicals to dogs in other breeds has not yet been determined.

What clinical signs or symptoms do dogs with TCC have? Blood in the urine, straining to urinate, and making repeated frequent attempts to urinate are the most frequent signs of TCC in dogs. Pet owners must realize, however, that a urinary tract infection will cause these same symptoms, so the symptoms alone do not necessarily mean the dog has TCC. Less commonly, dogs with TCC can have lameness due to spread of the tumor into the bones or spread into the lungs and a paraneoplastic syndrome called hypertrophic osteopathy.

How is TCC diagnosed? A diagnosis of TCC requires a tissue biopsy. Several other types of growths in the bladder, bladder infection, bladder stones, or bladder inflammation can cause similar symptoms as those in dogs with TCC. Some of these other conditions can also cause "masses" to be seen on radiographs or ultrasound, and these other conditions can cause abnormal cells in the urine, which can be mistaken for TCC. Therefore, the diagnosis of TCC requires a tissue biopsy. This is important because the treatment and prognosis depend entirely on exactly what is wrong with the bladder. A tissue biopsy can be obtained by surgery, cystoscopy (insertion of a fiberoptic scope into the bladder and biopsy through the scope), or in some cases with a urinary catheter.

What evaluation is needed for a dog with TCC? Once a diagnosis of TCC is made, it is important to determine the extent of the tumor, i.e. to perform "tumor staging". Tumor staging is performed to determine the best way to treat the cancer, to provide some information regarding prognosis, and to establish a baseline set of tumor measurements in order to determine if subsequent treatment is being successful. Tumor staging for TCC includes radiographs ("x-rays") of the thorax to look for lung metastasis, radiographs and ultrasound (or CT scan) of the abdomen to look for metastasis in the abdomen and to assess any changes in the kidneys that result from obstructed urine flow, and imaging of the bladder to determine the exact location and size of the tumor within the bladder (see Figure 1). This information is needed to best plan how to treat the cancer. Also, these tests are repeated during treatment to know if the treatment is being effective.

How is TCC treated? For dogs with TCC that has not spread beyond the bladder, surgical excision could be considered. In order to surgically excise the tumor, however, it needs to be located away from the neck (also called the trigone) of the bladder and the urethra. Several vital structures in the neck of the bladder (junction with ureters and urethra, urethral sphincter) usually prevent surgical excision of tumors in this location. This is especially true because malignant tumors, like TCC, need to be removed with a "margin" of normal tissue around the tumor. This "margin" often contains microscopic tumor cells that, left

Purdue University is an equal access/equal opportunity/affirmative action university.

behind, would result in cancer regrowth. In addition, most canine TCCs invade down into the bladder wall and therefore, surgical excision requires removal of a complete full thickness section of bladder wall. [Note: in humans with superficial, low grade cancer, this is not typically the case.] Because most canine TCCs are invasive into the bladder wall and located in the neck of the bladder, surgical removal is usually not possible. It has not yet been completely determined what benefit would occur from removing part of the tumor (in dogs in which the entire tumor cannot be removed).

If surgery is not possible, what other treatment options are available? Radiation therapy has been used to successfully control TCC growth in the bladder in dogs. Unfortunately, radiation given in traditional doses when applied to the bladder can lead to harmful complications including a scarred, shrunken bladder, and irritation to surrounding organs. One of the challenges in applying radiation to the bladder is that the bladder can move or flop within the abdomen and take on a different shape depending on how much urine is in the bladder and if structures next to the bladder such as the bowel are pushing in on the bladder. To use radiation therapy successfully in canine TCC, different treatment schemes need to be developed. Studies are underway, and results may help determine if radiation will have a role in treating TCC in dogs.

The vast majority of dogs with TCC are treated with medical therapy, i.e. with drugs. Three different drug protocols are used most often in the standard care for dogs with TCC. The first treatment protocol is to give a drug called piroxicam, or a piroxicam-like drug by itself. Piroxicam is a type of drug called a nonsteroidal antiinflammatory drug or "NSAID". NSAIDs block the cyclooxygenase (cox) enzyme, and are also referred to as "cox inhibitors". Cox inhibitors include piroxicam, aspirin, ibuprofen, Previcox, Deramaxx, Rimadyl, and others. There is an interesting history behind the use of cox inhibitors for the treatment of TCC in dogs. Veterinarians in the Purdue Comparative Oncology Program and a veterinarian colleague (Dr. T Needham, Wilmington N.C.) became interested in piroxicam several years ago when it was being used for pain relief in dogs with cancer, and unexpected remissions were noted. Two of the first dogs treated (one with metastatic carcinoma, one with undifferentiated sarcoma) had advanced cancer, and these dogs had remission of their cancer when receiving piroxicam, but no other treatment. This has led to numerous studies of piroxicam in animals with cancer at Purdue. In 62 dogs with TCC treated with piroxicam, the tumor went into complete remission in 2 dogs, decreased in size by $\geq 50\%$ in 9 dogs, remained "stable" in size ($<50\%$ change) in 35 dogs, and increased in size by $\geq 50\%$ in 16 dogs. Although remission is certainly the preferred treatment outcome, "stable disease" is also considered a beneficial response when the dog is feeling well and enjoying life. In that scenario, the cancer is "managed" as a chronic disease, and the dog lives with it. The median ("average") survival of the dogs treated with piroxicam was 195 days.

The second treatment protocol used as a standard treatment for dogs with TCC is to combine piroxicam with an intravenous chemotherapy drug called mitoxantrone. In a study performed by the Veterinary Cooperative Oncology Group, this combination treatment resulted in a remission rate of approximately 35%. In addition to dogs that had remission, 46% of the dogs also had "stable disease" where the cancer did not grow for a period of time. "Average" survival times with mitoxantrone/piroxicam have been in the 250-300 day range. Some dogs live much longer than this, while others do not live this long.

A third treatment that has gained attention in recent years is to use a drug called vinblastine to treat TCC. Vinblastine is a chemotherapy drug that is given intravenously at 2 week intervals in dogs with TCC. Although vinblastine has been used for decades to treat other cancers in dogs, it has only recently been appreciated for its benefit in dogs with TCC. In fact, an "accidental" discovery in cell culture studies revealed the benefit of this drug against TCC. Vinblastine resulted in remission in 35% of dogs, and stable disease (cancer control, but not shrink) in 50% of dogs in a study at Purdue University. A follow up study is addressing the question of whether piroxicam will make vinblastine work better, as is the case with some other chemotherapies.

Results of another treatment study are expected to be published in the next 6 months that define another treatment option for dogs with TCC, that is "metronomic" chemotherapy. The term metronomic chemotherapy is used to describe the frequent (typically daily), low dose, oral administration of chemotherapy. In order to be given daily, the drug doses are quite low. In fact at the doses used, the chemotherapy is probably not having direct cytotoxic activity, i.e. not directly killing the cancer cells. This type of chemotherapy schedule was developed with the goal to block the formation of new blood vessels in the cancer, that is to have an "anti-angiogenic" effect. If the cancer cannot gain access to new blood vessels, it cannot grow. Recently, other mechanisms of cancer control have also been proposed for this

Purdue University is an equal access/equal opportunity/affirmative action university.

metronomic treatment approach. The expected outcome of metronomic chemotherapy is that the cancer will stop growing for a period of time (ideally for many months or more). The cancer is not expected to shrink, but to stabilize in growth. Briefly, in a study at Purdue University, a series of 31 dogs with TCC were treated with low dose oral chlorambucil (also called leukeran). In the study, 1 dog had remission, and 20 dogs had stable disease, for a cancer control rate of 70%. This was encouraging since the cancer in all but 2 of the dogs had already developed resistance to other therapies. The median (“average”) length of life from the start of chlorambucil to death was 7 months, and this extended life was after other therapies had stopped working. The therapy was well tolerated with toxicity being very uncommon. The veterinarian can discuss with the pet owner whether “cancer control”, rather than cancer shrink is an appropriate goal for an individual dog.

Regardless of the treatment pursued, the typical plan followed in most dogs with TCC at Purdue University is to measure the extent of the tumor before treatment, and then to remeasure the tumor after 4-8 weeks of treatment (depending on the drug used). Various tests are also used to detect any side effects. If the tumor is shrinking or remaining stable in size after 4-8 weeks, and the dog is feeling well on that therapy, then the same treatment is continued. If the cancer is not responding, i.e. if it is growing, or if the dog does not feel well on that particular treatment, then a different treatment is initiated. After each 4-8 weeks of treatment the tumor is remeasured to confirm the treatment is still being beneficial.

Beyond the options discussed above, there are other treatments that can also help dogs with TCC. One of the more active types of TCC treatment in humans is “platinum” chemotherapy, primarily consisting of the drugs cisplatin and carboplatin. These drugs have had considerable antitumor activity against canine TCC as well. Cisplatin, however, is not used in dogs very commonly anymore because of risk of damage to the kidneys. Carboplatin is used, but needs to be dosed carefully to limit the risk of side effects. Carboplatin may have a new role when combined with a new type of drug – a demethylating agent. Stay tuned for results of ongoing research.

Pet owners that know humans with bladder cancer often ask why intravesical therapy is not done more often in dogs with TCC. Intravesical therapy, which refers to placing anticancer drugs directly into the bladder through a urinary catheter, is a mainstay in the treatment of humans with superficial TCC. The drug is expected to stay in the bladder where high concentrations can come in direct contact with the cancer. Initially, it was not known if intravesical therapy would be of benefit in dogs because TCC in dogs would be deeper in the bladder wall, and tumor masses would often be larger than those treated in humans. This would limit the access of the drug to the tumor. A clinical trial of intravesical therapy (specifically intravesical mitomycin C) in 12 dogs with TCC at Purdue University revealed two important findings. The first finding was that the antitumor effects were encouraging, consisting of partial remission in 5 dogs and stable disease in 7 dogs. Unfortunately, the second important finding was that in 2 dogs, the drug appeared to pass from the bladder into the blood stream and then throughout the body. These dogs had toxicity similar to what would occur with high dose intravenous chemotherapy. Although both dogs recovered, if a larger amount of drug were to be absorbed into the blood stream, it could cause more serious and life threatening side effects. For this reason, intravesical mitomycin C therapy is not typically given to dogs if there are other treatment options available.

In order to improve the outlook for dogs and human with invasive bladder cancer, the Purdue Comparative Oncology Program is conducting clinical trials in dogs with TCC. Dogs that take advantage of the clinical trials as well as standard care over the course of their cancer, can have longer survival, typically well beyond a year for many dogs. Clinical trials in dogs are similar to clinical trials in humans. The dogs live at home with their families, and come into the Purdue University Veterinary Teaching Hospital periodically for evaluation and treatment. Quality of life for the dogs is the highest priority, so treatments evaluated in clinical trials are selected with the goal of having antitumor effects with low risk of serious side effects. The advantages for a dog participating in a clinical trial are that the dog is receiving treatment that is expected to be as effective or more effective than standard therapies, the dog is helping veterinarians learn important information that is expected to help other dogs and even humans with bladder cancer, and the dog is receiving some “hope” if standard therapy has failed. In some instances, participating in a treatment trial is less expensive than other treatments.

Many pet owners have observed humans undergoing chemotherapy and are concerned that some of the serious side effects of chemotherapy in humans will also be observed in pet dogs. Fortunately, most dogs treated with chemotherapy, experience much less toxicity than humans receiving chemotherapy. The side effects of chemotherapy are considered acceptable in most dogs. Treatment protocols are selected with

Purdue University is an equal access/equal opportunity/affirmative action university.

the goal of maintaining or improving quality of life, at the same time the cancer is attacked. The pet owner should discuss the possible benefits and risk of specific medications that their dog may receive with the attending veterinarian. Cox inhibitors like piroxicam have few side effects. In some dogs (<20%), however, piroxicam will irritate the stomach or intestine. Therefore, if a dog on piroxicam has loss of appetite, vomiting, or dark tarry-looking stools, it is safest to stop the piroxicam and consult the veterinarian before starting the medication again. The new cox inhibitors, selective cox-2 inhibitors, are not expected to cause stomach irritation as frequently as piroxicam does.

What is the prognosis for dogs with TCC? Early studies reported survival in dogs with TCC as "0 days". At that time, it was thought there was "no hope" and many dogs were euthanized at the time of diagnosis. It is not known how long dogs with TCC that are not treated will live. Survival is affected by the growth rate of the tumor, the exact location of the tumor within the bladder, and whether the tumor has spread to other organs or not. The median ("average") survival in 55 dogs treated with surgery alone (before drugs that could help were identified) was 109 days. The median survival in dogs treated with early chemotherapy alone (cisplatin or carboplatin) at Purdue University was 130 days. Median survival with piroxicam treatment in 62 dogs with TCC was 195 days. As mentioned above, approximately 35% of dogs receiving mitoxantrone and piroxicam have remission, and the average survival is around 250-300 days. The survival times in all of these studies, however, varied tremendously from dog to dog. Some dogs died after only a few days, while others lived more than two years. As mentioned above, dogs who live the longest are those that receive more than one treatment protocol (one after the other switching therapies when the cancer begins to grow) during the course of the cancer. Factors that have been identified in our studies that negatively affect survival time include more extensive tumor within the bladder, spread of tumor beyond the bladder, and involvement of the tumor in the prostate gland. Regarding metastasis of TCC in dogs, approximately 20% of dogs with TCC have detectable metastasis at diagnosis, and 50-60% have metastasis at death.

Although progress has been made, and TCC is considered a very "treatable" disease, there is still much to be learned. We are not satisfied with the "efficacy" of current therapy, especially long term. Therefore, we are continuing to study TCC to determine better ways to prevent, manage, and treat this cancer.

What symptomatic care can be given to dogs with TCC? Dogs with TCC are very prone to developing bacterial infection (cystitis) in the bladder. Therefore, frequent urinalysis, culture, and treatment with antibiotics may be necessary. A secondary bacterial infection can result in a sudden worsening in symptoms (blood in urine, straining to urinate) in dogs with TCC, and these dogs will improve with treatment with antibiotics. A frustrating aspect of urinary tract infections that is being encountered more often in recent years is the development of bacterial infections that are resistant to commonly used antibiotics. These infections often require treatment with injectable antibiotic therapy.

TCC can block the flow of urine into and out of the bladder. Complete obstruction can rapidly lead to a buildup of urea and life-threatening complications. If urine flow is obstructed, stents (small tubes) can be placed in the ureters or urethra, as needed, to open up the "channels" and restore urine flow. Our group is working closely with Dr. Larry Adams, a veterinary urologist at Purdue, to provide this opportunity for dogs that need it. Urethral stents are typically placed with fluoroscopic guidance in a non-surgical procedure. Ureteral stents can be placed surgically, and in some cases non-surgically. Another approach to bypass urethral obstruction is to place a cystostomy tube (small diameter tube that goes from the bladder through the wall of the abdomen to the outside) to allow emptying of the bladder.

Can TCC be prevented? Steps that can be taken to reduce the risk of TCC in dogs, especially in dogs in high-risk breeds (Scottish terriers, West Highland white terriers, Wire hair fox terriers, Shetland sheepdogs, beagles) include: (1) avoiding older generation flea control products, i.e. flea dips, (2) avoiding lawns treated with herbicides and pesticides, and (3) feeding vegetables at least three times per week. These will reduce the risk of TCC, although some dogs will still develop the cancer if these recommendations are followed. There are other causes for TCC that have not yet been identified. The role of exposure to cigarette smoke in bladder cancer risk in dogs requires more study, but it would be best to limit exposure to smoke as it can cause other disease in dogs too.

TCC screening for early detection. The Wellness Clinic in the Purdue University Veterinary Teaching Hospital is providing a TCC screening program for older dogs in high-risk breeds (Scottish terriers, West Highland white terriers, Wire hair fox terriers, Shetland sheepdogs, beagles). The screening includes an ultrasound exam of the bladder and tests performed on the urine at six-month intervals. This program is considered optional in the care of dogs. Although the screening is expected to lead to earlier diagnosis

Purdue University is an equal access/equal opportunity/affirmative action university.

and the chance to treat the cancer before it becomes advanced, it is not yet known if this screening program will improve the outlook for dogs or not. Pet owners who wish to schedule an appointment or check the availability and costs of the program can call the Purdue Small Animal Clinic at 765 494-1107. Stay tuned, as an expanded option for TCC screening is under development in 2013.



What can be learned from dogs with TCC that will help human cancer patients?

In the Purdue Comparative Oncology Program at Purdue University, we study specific forms of naturally-occurring cancer in pet dogs in order to learn new information to help animals and to help human cancer patients. This is possible because certain naturally occurring canine cancers greatly resemble that same form of cancer in humans. This is true with bladder cancer. Canine TCC is almost identical to human invasive TCC in histopathologic characteristics, molecular features studied to date, biologic behavior (sites and frequency of metastasis), and response to medical therapy. Our laboratory is studying the risk factors (environmental and genetic) for TCC, methods to detect TCC earlier, and methods to more effectively treat TCC. These studies are expected to benefit

both animals and humans with cancer. In fact, our work has already led to clinical trials in humans with TCC at the Indiana University School of Medicine.

Canine Bladder Cancer Clinic at Purdue University. Within the Oncology Section in the Purdue University Veterinary Teaching Hospital, a Canine Bladder Cancer Clinic has been established to care for dogs that have TCC or dogs suspected of having TCC. The clinic is staffed by Dr. Deborah Knapp, other veterinarians specializing in oncology, veterinary technicians, and assistants. Diagnostic procedures including cystoscopy, cancer staging tests, and multiple types of therapy are offered. The Canine Bladder Cancer Clinic also has ongoing clinical trials to help dogs with TCC while learning new information that can help other dogs and potentially humans with this cancer. Veterinarians in the Bladder Cancer Clinic work closely with primary care veterinarians in the dog's home town to provide the most complete care. If you would like to schedule an appointment, please call the reception staff at 765 494-1107, or you may call our Clinical Trials Coordinator, Ms. Patty Bonney at 765 494-1130.

Recent Publications and Selected Earlier Publications Related to Bladder Cancer:

Dhawan D, Ramos-Vara JA, Naughton JF, Cheng L, Low PS, Rothenbuhler R, Leamon CP, Parker N, Klein PJ, Vlahov IR, Reddy JA, Koch M, Murphy L, Fourez LM, Stewart JC, Knapp DW. Targeting folate receptors to treat invasive urinary bladder cancer. *Cancer Res* 2013;73:875-84.

Knapp DW, Henry CJ, Widmer WR, Tan KM, Moore GE, Ramos-Vara JA, Lucroy MD, Greenberg CB, Greene SN, Abbo AH, Hanson PD, Alva R, Bonney PL. Randomized trial of cisplatin versus firocoxib versus cisplatin/firocoxib in dogs with transitional cell carcinoma of the urinary bladder. *J Vet Intern Med* 2013; 27:126-133.

Higuchi T, Burcham GN, Childress MO, Rohleder JJ, Bonney PL, Ramos-Vara JA, Knapp DW. Characterization and treatment of transitional cell carcinoma of the abdominal wall in dogs: 24 cases (1985-2010). *J Am Vet Med Assoc.* 2013; 15;242:499-506.

Dhawan D, Ramos-Vara JA, Hahn NM, Waddell J, Olbricht GR, Zheng R, Stewart JC, Knapp DW. DNMT1: An emerging target in the treatment of invasive urinary bladder cancer. *Urol Oncol* 2012 May 18. [Epub ahead of print].

Zhang J, Wei S, Liu L, Nagana Gowda GA, Bonney P, Stewart J, Knapp DW, Raftery D. NMR-based metabolomics study of canine bladder cancer. *Biochim Biophys Acta* 2012;1822:1807-14.

Hahn NM, Bonney PL, Dhawan D, Jones DR, Balch C, Guo A, Hartman-Frey C, Fang F, Parker HG, Kwon EM, Ostrander EA, Nephew KP, Knapp DW. Subcutaneous 5-azacitidine treatment of naturally-occurring canine urothelial carcinoma: a novel epigenetic approach to human urothelial carcinoma drug development. *J Urol* 2012;187:302-9.

McMillan SK, Knapp DW, Ramos-Vara JA, Bonney PL, Adams LG. Outcome of urethral stenting for management of obstruction secondary to transitional cell carcinoma in 19 dogs (2007-2010). *J Amer Vet Med Assoc* 2012;241:1627-32.

Purdue University is an equal access/equal opportunity/affirmative action university.

Naughton JF, Widmer WR, Constable D, Knapp DW. Accuracy of three-dimensional and two-dimensional ultrasonography in measuring tumor volume in dogs with transitional cell carcinoma of the urinary bladder. *Am J Vet Research* 2012;73:1919-24.

Childress MO, Adams LG, Ramos-Vara J, Freeman LJ, He S, Knapp DW. Comparison of cystoscopy vs surgery in obtaining diagnostic biopsy specimens from dogs with transitional cell carcinoma of the urinary bladder and urethra. *J Amer Vet Med Assoc* 2011;239:350-6.

McMillan SK, Boria P, Moore GE, Widmer WR, Bonney PL, Knapp DW. Antitumor effects of deracoxib treatment in 26 dogs with transitional cell carcinoma of the urinary bladder. *J Amer Vet Med Assoc* 2011;239:1084-9.

Arnold EA, Childress MO, Fourez LM, Tan KM, Stewart JC, Bonney PL, Knapp DW. Phase II clinical trial of vinblastine in dogs with transitional cell carcinoma of the urinary bladder. *J Vet Intern Med* 2011; 25:1385-1390.

Abbo AH, Jones DR, Masters AR, Stewart JC, Fourez L, Knapp DW. Phase I clinical trial and pharmacokinetics of intravesical Mitomycin C in dogs with localized transitional cell carcinoma of the urinary bladder. *J Vet Intern Med* 2010 24:1124-30.

Dhawan D, Craig BA, Cheng L, Snyder PW, Mohammed SI, Stewart JC, Zheng R, Loman RA, Foster RS, Knapp DW. Effects of short-term celecoxib treatment in patients with invasive transitional cell carcinoma of the urinary bladder. *Mol Cancer Ther* 2010;9:1371-1377.

Dhawan D, Ramos-Vara JA, Stewart JC, Zheng R, Knapp DW. Canine invasive transitional cell carcinoma cell lines: in vitro tools to complement animal model of invasive urinary bladder cancer. *Urolog Oncol* 2009; 27:284-292.

Dill AL, Ifa DR, Manicke NE, Costa AB, Ramos-Vara JA, Knapp DW, Cooks RG. Lipid profiles of canine invasive transitional cell carcinoma of the urinary bladder and adjacent normal tissue by desorption electrospray ionization imaging mass spectrometry. *Analytical Chemistry* 2009; 81:8758-8764.

Dhawan D, Jeffreys AB, Zheng R, Stewart JC, Knapp DW. Cyclooxygenase-2 dependent and independent antitumor effects induced by celecoxib in urinary bladder cancer cells. *Mol Cancer Ther* 2008, 7:897-904.

Wilson CR, Regnier FE, Knapp DW, Raskin RE, Andrews DA, Hooser SB. Glycoproteomic profiling of serum peptides in canine lymphoma and transitional cell carcinoma. *Vet Comp Oncology* 2008; 6:171-181.

Knapp DW, Adams LG, Degrand AM, Niles JD, Ramos-Vara JA, Weil AB, O'Donnell MA, Lucroy MD, Frangioni JV. Sentinel lymph node mapping of invasive urinary bladder cancer in animal models using invisible light. *Eur Urol* 2007; 52:1700-1708.

Mohammed SI, Deepika D, Abraham S, Snyder PW, Waters DJ, Lu M, Wu L, Zheng R, Stewart J, Knapp DW. Cyclooxygenase inhibitors in urinary bladder cancer: in vitro and in vivo effects. *Mol Cancer Ther* 2006; 5:329-336.

Abraham S, Knapp DW, Cheng L, Snyder PW, Mittal SK, Bangari DS, Kinch M, Wu L, Dhariwal J, Mohammed. Expression of EphA2 and Ephrin A-1 in carcinoma of the urinary bladder. *Clin Cancer Res* 2006;12:353-360.

Boria PA, Glickman NW, Schmidt BR, Widmer WR, Mutsaers AJ, Adams LG, Snyder PW, DiBernardi L, de Gortar AE, Bonney PL, *Knapp DW. Carboplatin and piroxicam in 31 dogs with transitional cell carcinoma of the urinary bladder. *Vet Comp Oncol* 2005;3:73-80.

Raghavan M, Knapp DW, Bonney PL, Dawson MH, Glickman LT. Evaluation of the effect of dietary vegetable consumption on reducing risk of transitional cell carcinoma of the urinary bladder in Scottish Terriers. *J Am Vet Med Assoc* 2005;22:94-100.

Raghavan M, Knapp DW, Dawson MH, Bonney PL, Glickman LT. Topical spot-on flea and tick products and the risk of transitional cell carcinoma of the urinary bladder in Scottish Terrier dogs. *J Am Vet Med Assoc* 2004;225:389-94.

Glickman LT, Raghavan M, Knapp DW, Bonney PL, Dawson MH. Herbicide exposure and the risk of transitional cell carcinoma of the urinary bladder in Scottish Terrier dogs. *J Am Vet Med Assoc* 2004;1290-1297.

Mohammed SI, Craig BA, Mutsaers AJ, Glickman NW, Snyder PW, deGortari AE, Schlittler DL, Coffman KT, Bonney PL, Knapp DW. Effects of the cyclooxygenase inhibitor, piroxicam in combination with chemotherapy on tumor response, apoptosis, and angiogenesis in a canine model of human invasive urinary bladder cancer. *Mol Cancer Ther* 2003;2:183-188.

Mohammed SI, Bennett PF, Craig BA, Glickman NW, Mutsaers AJ, Snyder PW, Widmer WR, DeGortari AE, Bonney PL, Knapp DW. Effects of the cyclooxygenase inhibitor, piroxicam, on tumor response, apoptosis, and angiogenesis in a canine model of human invasive urinary bladder cancer. *Cancer Res* 2002;62:356-358.

Knapp DW, Glickman NW, DeNicola DB, Bonney PL, Lin TL, Glickman LT. Naturally-occurring canine transitional cell carcinoma of the urinary bladder, a relevant model of human invasive bladder cancer. Invited submission to *Urol Oncol* 2000;5:47-59.

Knapp DW, Richardson RC, Chan TCK, Bottoms GD, Widmer WR, DeNicola DB, Teclaw R, and Bonney PL. Piroxicam therapy in 34 dogs with transitional cell carcinoma of the urinary bladder. *J Vet Intern Med* 1994;8:273-278.

Knapp, DW, Richardson RC, Bottoms GD, Teclaw R, Chan TC. Phase I trial of piroxicam in 62 dogs bearing naturally occurring tumors. *Cancer Chemother Pharmacol* 1992;29:214-218.