



EQUINE HEALTH UPDATE

FOR HORSE OWNERS AND VETERINARIANS

The Heart of the Matter: CAN A HORSE WITH A HEART MURMUR STILL PERFORM?

By Laura Brink, DVM Student (Class of 2021)
Edited by Dr. Stacy H. Tinkler, Large Animal Internal Medicine

Finding out that your horse has a heart murmur may come as a surprise, especially if your companion has no outward signs of heart disease. The good news is that many horses are able to continue their current lifestyle without negative effects; however, moderate to severe murmurs due to underlying cardiac disease may have potentially devastating consequences.

The Healthy Equine Heart

A horse's heart consists of four chambers and four valves through which blood flows in an organized fashion (**Figure 1**). Oxygen-poor blood from the body enters the right atrium, flows through the tricuspid valve, and into the right ventricle. It then passes through the pulmonary valve into the pulmonary arteries where it becomes oxygen-rich in the lungs. From the lungs, blood flows through the pulmonary veins into the left atrium, then through the mitral valve into the left ventricle. Finally, blood passes through the aortic valve into the aorta for distribution to the body. Coordinated timing of valve closure and opening allows for efficient blood flow.

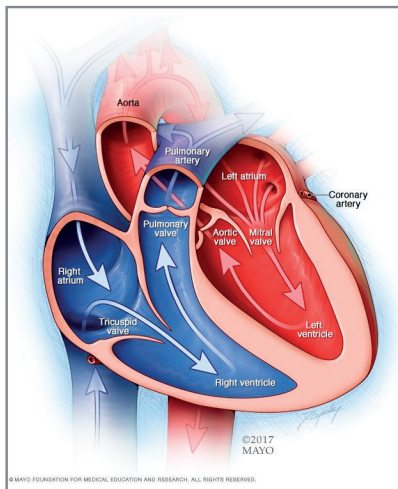


Figure 1. Normal heart

Equine Heart Murmurs

The usual “lub-dub” of the heart beat is due to synchronized closure of the mitral and tricuspid valves (“lub”), then the synchronized closure of the pulmonary and aortic valves (“dub”). If a valve fails to open or close appropriately, another sound may be heard that is due to abnormal blood flow within the heart. This other sound is referred to as a heart murmur. There are two types of heart murmurs—physiologic—where the murmur is due to turbulent blood flow through a normal heart or pathologic—where the murmur is caused by a cardiac or valve defect. In order to determine the possible causes of a murmur, it

(continued on page 2)

VOL. 23, ISSUE NO. 1 - 2021



CONTENTS

Medicine

- Heart Murmurs pg. 1
- Clostridial Enterotoxemia
in Neonatal Foals pg. 4

Surgery

- Equine Rehabilitation. pg. 5
- Dorsal Metacarpal Disease
of Thoroughbreds. pg. 7

News & Notes

- Mysterious Liver Disease . . . pg. 3
- Who's Who pg. 6

In Depth

- Clostridial Enterotoxemia . . . pg. 4



Visit vet.purdue.edu/ePubs
for more information on
how to access the newsletter
through our PVM ePubs app.

Heart Murmur *(continued from cover)*

must be characterized by its location, timing, and intensity and will be assigned a grade from 1-6 by your veterinarian, based on its intensity and loudness. It is important to note that a higher grade does not always mean the cause of the murmur is more severe.

In adult horses, two of the most common pathologic heart murmurs are due to aortic insufficiency (AI), or aortic valve regurgitation, and mitral insufficiency (MI), or mitral regurgitation. They are commonly caused by valve degeneration, in which the affected valve(s) cannot close properly, leading to backflow of blood and an audible heart murmur (**Figures 2 and 3**). Valvular degeneration is considered, in part, to be a normal aging change, though other underlying processes may also play a role. For example, severe MI can also be caused by inflammation from infection and may also arise secondary to chamber dilation due to progressive AI, or as a result of a birth defect.

Aortic valve regurgitation (AI) occurs most often in horses 10 years of age or older and studies have shown that male horses are more likely to develop AI than females. Generally, AI is a slowly progressive disease, meaning it worsens slowly over time. It often presents mildly with the majority of horses experiencing few to no changes in performance. Similarly, mitral valve regurgitation (MI) occurs most often in horses 15 years of age or older. MI progresses and presents in a similar fashion to AI, with slow progression and minimal impact on performance.

In cases of moderate to severe AI or MI, the changes in blood flow and blood volume within the different chambers of the heart can be detrimental. Moderate to severe AI causes the left ventricle to dilate (stretch in size), making it difficult to pump blood out of the heart. This can lead to cardiac arrhythmias (abnormal rhythms) and subsequent heart failure, which may be noticed by owners as intolerance of normal exercise, difficulty breathing, cough, edema, lethargy, and clear nasal discharge. Sudden death from arrhythmia may also occur. Moderate to severe MI leads to dilation of the left atrium and is poorly tolerated with horses more prone to developing arrhythmias and/or heart failure than those with AI alone.

Moving Forward—Work-Up, Management, and Prognosis

Once a murmur is identified, the goal is to determine the source and the severity of any underlying disease. To do this, an echocardiogram (ultrasound of the heart) will be performed to look at the heart's structure and function, as well as an electrocardiogram (ECG) to evaluate the heart's rhythm. Additional tests may be recommended depending on the patient.

Management of pathophysiologic heart murmurs is targeted at monitoring for worsening of disease. Yearly or twice-yearly exams with echocardiogram and ECG is recommended depending on severity of disease. In horses that develop congestive heart failure, medical therapy can be considered.

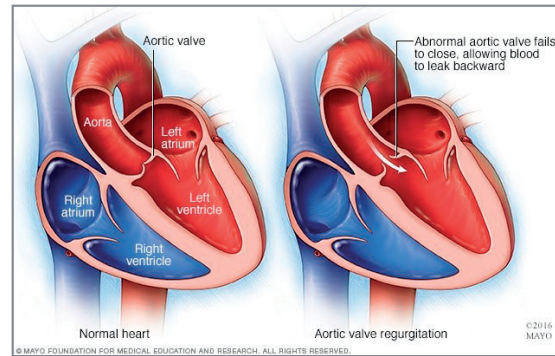
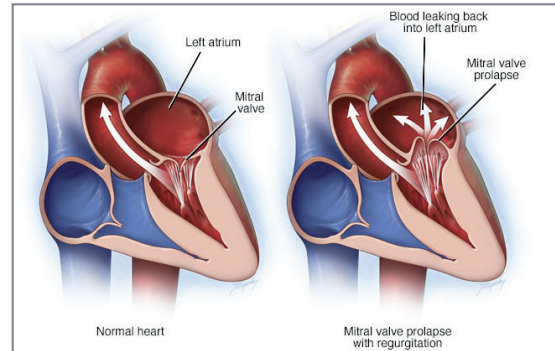


Figure 2. Aortic insufficiency (AI)

Figure 3. Mitral insufficiency (MI)



Overall, the decision whether or not a horse with a heart murmur can continue its current lifestyle is patient dependent. Patient safety, health, and rider/driver safety must all be considered prior to making this decision. Most horses with mild AI or MI can continue their normal lifestyle; however, horses with severe disease, heart failure, arrhythmias or heart chamber dilation should not be ridden due to welfare concerns for the horse and for rider safety due to the risk for sudden death.

References

1. Marr CM. Equine Acquired Valvular Disease. *Vet Clin North Am Equine Pract.* 2019 Apr;35(1):119-137. doi: 10.1016/j.cveq.2018.12.001. Epub 2019 Mar 11. PMID: 30871831.
2. Reef VB, Bonagura J, Buhl R, McGurrrin MK, Schwarzwald CC, van Loon G, Young LE. Recommendations for management of equine athletes with cardiovascular abnormalities. *J Vet Intern Med.* 2014 May-Jun;28(3):749-61. doi: 10.1111/jvim.12340. Epub 2014 Mar 14. PMID: 24628586; PMCID: PMC4895474.
3. Keen JA. Equine aortic regurgitation: The search for objective repeatable and reproducible indicators of severity. *Vet J.* 2016 Jul;213:91-2. doi: 10.1016/j.tvjl.2016.04.016. Epub 2016 May 4. PMID: 27240924.
4. Bonagura JD. Overview of Equine Cardiac Disease. *Vet Clin North Am Equine Pract.* 2019 Apr;35(1):1-22. doi: 10.1016/j.cveq.2019.01.001. Epub 2019 Mar 11. PMID: 30871827.
5. Ven S, Declodt A, De Clercq D, Vera L, Rademakers F, van Loon G. Detection of subclinical left ventricular dysfunction by tissue Doppler imaging in horses with aortic regurgitation. *Equine Vet J.* 2018 Sep;50(5):587-593. doi: 10.1111/evj.12805. Epub 2018 Feb 1. PMID: 29341213.
6. Ven S, Declodt A, Van Der Vekens N, De Clercq D, van Loon G. Assessing aortic regurgitation severity from 2D, M-mode and pulsed wave Doppler echocardiographic measurements in horses. *Vet J.* 2016 Apr;210:34-8. doi: 10.1016/j.tvjl.2016.01.011. Epub 2016 Jan 18. PMID: 26900009.
7. Redpath A, Bowen M. Cardiac Therapeutics in Horses. *Vet Clin North Am Equine Pract.* 2019 Apr;35(1):217-241. doi: 10.1016/j.cveq.2018.11.004. Epub 2019 Mar 11. PMID: 30871828.
8. Campbell, F. E. (2013). *Cardiac Disease and Examination - WSAVA2013.* VIN. <https://www.vin.com/apputil/content/defaultadv1.aspx?pld=11372&id=5709745&print=1>.
9. Aortic valve regurgitation. (2020, August 7). Pictures Only. <https://www.mayoclinic.org/diseases-conditions/aortic-valve-regurgitation/symptoms-causes/syc-20353129>.

News & Notes

MYSTERIOUS LIVER DISEASE IN MIDWESTERN HORSES

By Drs. Sandra Taylor and Carla Olave, Large Animal Internal Medicine

In the autumn of 2020, sporadic cases of equine hepatitis began surfacing in several Midwestern states. The first symptoms were high fevers (up to 107°F!) and decreased appetite, with most affected horses then developing jaundice (yellowing of the gums and whites of the eyes; **Figure 1**). Blood work pointed to an inflammatory process with increases in liver enzyme activity. Fevers typically responded well to non-steroidal anti-inflammatory drugs, such as flunixin meglumine (Banamine®), but a second cycle of fevers was observed 1 - 2 weeks after the first cycle had ended. In a few horses, a third fever cycle was noted.

Initially, veterinarians suspected that these were cases of infectious gastrointestinal (GI) disease with secondary liver involvement (i.e. compression of the bile duct by a large, inflamed colon or backflow of intestinal bacteria up the bile duct into the liver),¹ but GI tests were normal. Stumped, veterinary internal medicine specialists (internists) at Purdue University began testing for everything under the sun, including COVID-19 (SARS-Cov-2)! Luckily, testing for COVID-19, anaplasmosis, leptospirosis, equine hepatitis viruses (equine parvovirus-hepatitis and equine hepatitis virus), pathogenic equine respiratory viruses, Strangles, and pathogenic GI bacteria and viruses were negative. Although the livers of affected horses appeared normal on ultrasound examinations, liver biopsies showed significant liver inflammation (hence, the diagnosis of “hepatitis”). Some horses also had areas of necrosis (dead tissue) within the liver. Given the appearance of several types of inflammatory cells, it was difficult to know what type of insult the livers had suffered: bacterial? viral? fungal? toxic? To try to answer that question, liver and blood samples from affected horses were sent to laboratories throughout the country for unique, highly sophisticated molecular diagnostic testing in an effort to identify possible new pathogens. To date, no cause for this disease has been identified; efforts are ongoing.²

The good news? No affected horses that were presented to Purdue University with this idiopathic hepatitis syndrome developed liver failure. Also, all horses recovered clinically within 6 weeks of the first spike in rectal temperature and returned to their previous level of work. Antibiotics did not appear to be necessary for clinical recovery. However, follow-up liver biopsies in affected horses have shown improved but ongoing inflammation, even 3 - 4 months after clinical resolution.

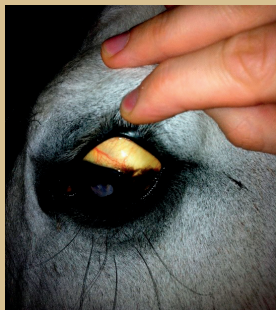


Figure 1. Jaundice (icterus) of the sclera in a horse.

It is unknown how long complete healing will take, and whether or not the liver will be scarred in the future. The other silver lining is that no new cases have been reported since April of 2021.

So what's going on? Purdue University pathologists and collaborating researchers around the country have been instrumental in getting to the bottom of this new syndrome. Although the cause has not been identified, several important diseases have been ruled out, including Theiler's disease (equine serum hepatitis), which has recently been discovered to have an association with equine parvovirus-hepatitis.^{3,4} According to pathologists, it is unlikely that a toxin is involved given the microscopic appearance of the liver biopsies. Therefore, an infectious agent is most likely, and if this is true, it is unknown whether this agent is contagious to other horses. The majority of affected horses were in contact with unaffected horses, but a few farms reported more than one horse being affected. In addition, it is unknown whether or not new cases will be seen this coming autumn or winter. Perhaps this novel syndrome is seasonal, or maybe there was bacterial or viral contamination of an equine product. Importantly, epidemiological surveys have not identified a common thread among affected horses.

In summary, a new, apparently transient, hepatitis syndrome has been identified in Midwestern horses, the etiology of which is still unknown. Although we hope to never encounter this disease again, if it does return, additional blood and liver testing will be important in identifying a cause and helping determine long-term prognosis. As with any horse that demonstrates a decreased appetite and/or fever, please call your veterinarian immediately if you notice these signs. Do not administer anti-inflammatory medications (such as Banamine® or phenylbutazone/Bute) unless advised by your veterinarian. If this novel hepatitis syndrome recurs in previously affected horses or if new cases are detected, funds are available for testing. Fingers crossed that we won't need to use them, but please call Dr. Taylor in the Large Animal Clinic if you suspect that your horse has this condition or if you have any questions. Liver biopsies are performed under standing sedation and pose very little risk in most cases.

References:

1. Davis JL, Blikslager AT, Catto K, et al. A retrospective analysis of hepatic injury in horses with proximal enteritis (1984-2002). *J Vet Intern Med* 2003;17(6): 896-901.
2. Taylor SD, Kritchevsky JE, Slovis NM, et al. Emerging outbreak of hepatitis in Midwestern horses. *J Am Vet Med Assoc* 2021;258(11): 1183.
3. Tomlinson JE, Kapoor A, Kumar A, et al. Viral testing of 18 consecutive cases of equine serum hepatitis: a prospective study (2014-2018). *J Vet Intern Med* 2019;33(1):251-257.
4. Divers TJ, Tennant BC, Kumar A, et al. New parvovirus associated with serum hepatitis in horses after inoculation of common biological pro

Clostridial Enterotoxemia in Neonatal Foals

By Alicia Van Matre, DVM Student (Class of 2021) – Edited by Dr. Sandra Taylor, Large Animal Internal Medicine

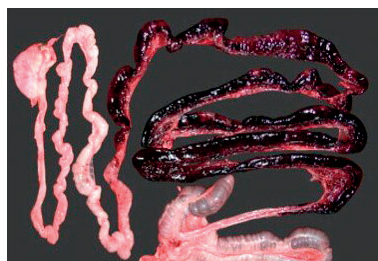There are many organisms that cause diarrhea in neonatal foals including *Salmonella* spp, *Rotavirus*, *Cryptosporidium parvum*, and *Clostridium* spp. Of these organisms, the clostridial bacteria result in the highest morbidity (illness) and mortality. In particular, the species to be aware of are *Clostridium perfringens* and *Clostridium difficile*. These bacteria cause disease through their ability to produce enzymes called exotoxins. An exotoxin is a protein produced from a live bacterium that is excreted into its surroundings, causing tissue damage. An endotoxin, by comparison, is a protein released when a bacterium is lysed (ruptured), and is also toxic to the surrounding environment. Endotoxins are primarily produced by Gram-negative bacteria, while exotoxins can be produced by Gram-positive bacteria, such as *Clostridium* spp, or Gram-negative bacteria.

Which toxins do *C. perfringens* and *C. difficile* produce?

C. perfringens and *C. difficile* can each produce several exotoxins depending on the bacterial strain. Regarding *C. perfringens*, researchers have divided the types of exotoxins into two categories: major and minor toxins. Major toxins are the exotoxins that research has proven to be lethal in mice. Minor toxins, on the other hand, still cause disease but are considered non-lethal. The major toxins include alpha, beta, epsilon, and iota and the strains of *C. perfringens* are classified based on which of these toxins they produce. Typically, Types A through E are the most common, but Type F and Type G have also been identified. The types that are most concerning in neonatal foals are *C. perfringens* Type A and Type C, due to the severity of disease they cause. *C. difficile*, by comparison, produces fewer exotoxins, two of which have been most associated with disease in foals. These toxins are Toxin A and Toxin B. They are similar in structure but are categorized differently: Toxin A is considered an enterotoxin and results in hemorrhage and damage to the mucosal lining of the intestines while Toxin B is a cytotoxin and it damages individual cells. Foals can become sick from either one or both toxins.

How do *C. perfringens* and *C. difficile* cause disease and what are the signs?

For both species of *Clostridium*, the bacteria enter the foal's body through ingestion. The most common source of *C. perfringens* is the dam; mares can shed the bacteria in their feces. When the newborn foal suckles or noses around its stall or paddock, they can ingest this bacteria. In some foals, the bacteria can produce toxins that cause inflammation of the intestines, which is termed "enterocolitis" (Figure 1). *C. difficile* works in a similar fashion: the foal ingests the bacteria from the environment and Toxins A and/or B can cause inflammation of the intestines. One important reason that neonatal foals are at risk for developing clostridial



enterocolitis is because colostrum contains proteins that block an enzyme that

Figure 1. Necrotic and hemorrhagic small intestine in a foal with clostridial enterocolitis. (Uzal, Vet Micro, 2012)

can break down clostridial toxins. Therefore, most foals that develop clostridial enterocolitis have adequate passive transfer of colostral immunity.

Clinical signs of clostridial enterocolitis vary from mildly soft feces to severe watery and hemorrhagic diarrhea. Abdominal bloat is common since the bacteria can produce gas; this can cause colic and even intestinal rupture. Foals become dehydrated secondary to anorexia and diarrhea. In foals with enterocolitis, inflamed and damaged intestine can allow absorption of *Clostridium* spp. and normal intestinal flora from the gut into the blood. The presence of bacteria and toxins in the blood is termed "septicemia;" bacteria can then travel to joints, bones and the central nervous system and cause multiple organ damage.

Although clostridial bacteria can cause enterocolitis and septicemia in neonatal foals, not all foals that ingest *Clostridium* spp. get sick. In fact, *C. perfringens* Type A and *C. difficile* make up part of the normal bacterial flora of the foal's gut and usually do not cause disease unless the bacterial strain is particularly virulent or a large amount of bacteria is ingested. In addition, foals with concurrent illness are at higher risk of developing enterocolitis from clostridial bacteria because of a weakened immune system. Conversely, *C. perfringens* Type C is never considered part of the normal flora of the foal's gut. Type C typically causes more serious disease than Type A or *C. difficile* because Type C produces the *C. perfringens* beta (CPB) exotoxin. CPB is a necrotizing toxin, meaning it forms holes in the membranes of the cells it contacts, causing the death of those cells and the surrounding tissue.

Treatment and prognosis

Treatment of clostridial enterocolitis depends on severity of illness but often requires hospitalization and intensive care. Fluid and electrolyte therapy is typically required to correct dehydration and electrolyte loss from diarrhea. Antibiotic therapy is necessary in septicemic foals and is often given to specifically kill clostridial bacteria. Other treatments include the clostridial toxin binder, di-tri-octahedral smectite (Biosponge™), as well as lactase enzyme to aid in digestion. Plasma might be necessary to replace blood protein that is lost in diarrhea and to improve blood pressure in some cases. In severe cases, parenteral (intravenous) nutrition might be required while the gut heals.

The survival rate of foals infected with *C. perfringens* Type C is 50% compared to 70% of those infected with *C. perfringens* Type A and *C. difficile*. The severity and rapid progression of these infections is why it is imperative that these foals are assessed by a veterinarian at the onset of clinical signs. Aggressive treatment is critical for a positive outcome.

Can clostridial enterocolitis be prevented?

Clostridial infections usually develop within the first week of life. Therefore, all foals must be watched carefully over the first several days following birth, even if the foal nursed colostrum well. Unfortunately, there are no specific protocols available that can guarantee the prevention of a clostridial infection. The bacterial spores are resistant to many disinfectants and can survive in the

(continued on page 6)

THE CURRENT STATE OF

Physical Rehabilitation in Equine Medicine

Co-authored by Shelby Cipolla, DVM Student (Class of 2021) and Dr. Caroline Gillespie Harmon, Equine Field Service

Physical rehabilitation has a plethora of potential applications within equine medicine—including post-operative recovery, following an injury or period of decreased activity, neurologic conditions, and improving strength and balance in a patient. In fact, there are few horses who would not benefit from some form of rehabilitation, whether fit or debilitated. The many varied goals of veterinary rehabilitation are to reduce pain, enhance tissue healing, improve endurance and muscle strength and ultimately to restore the animal to its previous activity level all while trying to prevent additional injury.¹ The field of equine rehabilitation includes the following modalities: hydrotherapy, dynamic mobilization (stretching), acupuncture, structured exercise programs, extracorporeal shockwave therapy, therapeutic laser treatment, and many others.² This article seeks to review the possible indications and benefits of some of the physical rehabilitation methods currently available.

One of the most frequently utilized rehabilitation methods is hydrotherapy (applying water to encourage healing). There are four types of equine hydrotherapy: swimming—which can help horses rehabilitate after injuries such as ligament damage, water treadmills—which can improve a horse's range of motion, equine spas—where the cooler water temperatures can decrease inflammation, and cold hosing. Cold water hydrotherapy has a wide range of indications including but not limited to wounds, laminitis (acute and chronic), and cellulitis.³ Responses to this treatment include benefits such as decreased inflammation, pain reduction, locally restricted blood flow and decreased local metabolism. Alternatively, hot water hydrotherapy is indicated in situations where increased tissue stretching is required and in injuries that are at least 72 hours old. Therapeutic results include an increase in local blood flow and local metabolism, reduction of muscle spasms, increased extensibility of local tissues, and decreased pain.⁴

Another therapeutic modality commonly performed is dynamic mobilization, or more simply “carrot stretches.” Appropriately named, “carrot stretches” involve luring the equine patient into a particular position with a treat and holding the position for a predetermined amount of time. Beneficial to almost any horse, these stretches focus on strengthening and balancing the core muscles while also increasing flexibility. They have been proven to increase the size of the muscles most influential in stabilizing the spine, the multifidus muscles.⁴ These stretches can be used to help prepare young horses to be trained under saddle, older horses to maintain strength and flexibility, athletic horses to increase their performance capabilities, and following injury or surgery to build up strength prior to a gradual return to work.⁵ An additional benefit of dynamic mobilization is that there are many stretches that can be used by owners at their home stable.

Acupuncture incorporates the insertion of fine needles through the skin in specific spots identified as treatment locations (acupoints). These are typically associated with a significant response from the horse through a variety of neurologic mechanisms and actions as well as connective tissue and fascial mechanisms that are beyond



Dr. Jennifer Koziol performing acupuncture on a horse.

- the scope of this article. When placed, the needles are often
- twisted and allow for the tissue to grip them and then stretch.
- This produces relaxation of the tissues and release of an analgesic.
- Acupuncture is a valuable tool in multi-modal therapy by helping
- quiet down triggered areas and allowing other treatments to work,
- but it is still important to find the primary underlying cause of
- pain in any patient if you want resolution of the ongoing problem.¹

- Exercise programs are utilized in order to gain muscle, tendon or
- ligament strength, or flexibility. They can include everything from
- hand walking, jogging in hand, walking under saddle, walking
- over cavalettis or up and down hills, and slowly increasing the
- amount or duration of activity over time. Horses are often started
- back to work after an injury slowly with some combination of the
- above regimens. This allows for the tissues to gain strength while
- preventing further damage to the healing tissue. Your veterinarian
- may ask you to return them to their normal work load over the
- course of one to two months or over as long as a year. Occasionally
- a treadmill is utilized as a method of providing exercise in a very
- controlled manner.



A patient undergoing shockwave treatment for a severely damaged ligament.

Extracorporeal shockwave is when pressure waves are generated and focused to then penetrate the tissue in question. This ultimately leads to micro-trauma which increases blood flow and nutrients to the desired area. Shockwave also provides some pain control. This is most prominent at 48 hours after treatment and is important because your horse may feel better and injure tissue that they are not protecting. Shockwave treatments are usually performed every 2-3 weeks and are typically used for tendon and ligament issues but it certainly can be utilized for back pain.⁶

- Another commonly utilized rehabilitation method is laser therapy.
- This includes using a therapeutic low-level laser on a wounded or
- painful area in order to reduce inflammation and pain, increase
- endorphins, and stimulate healing (depending on the dose used).

CONTINUED ON PAGE 6

News & Notes

MEET OUR TREATMENT TECHNICIANS



My name is Allison Bayless. I am a registered veterinarian technician (RVT) at Purdue University Large Animal Hospital! I am a treatment technician and surgery on-call technician. I enjoy teaching fourth year veterinary students on their clinical rotations, interacting with clients, and caring for patients. Continually learning and meeting new people at

Purdue makes for a valuable experience. I enjoy showing goats, judging livestock shows, traveling, hiking and kayaking in my free time.



My name is Kim Whitcomb and I am an RVT (registered veterinary technician) that works as one of the members of the Large Animal Treatment Team. I graduated from Purdue's Veterinary Nursing Program in 2019. Upon graduation I started working at Purdue as a treatment tech. Purdue has definitely allowed me to grow into a better technician and in the

process I have learned so much. I love how I get to do so much with the patients and being able to help the students grow has been rewarding as well. In my free time I love to play softball, walks with my Golden Retriever, and hanging out with friends and family.

Clostridial Enterotoxemia

(continued from page 4)

environment for extended periods of time. Good biosecurity and hygiene practices are the most important components of prevention. Simple measures such as cleaning stalls regularly to remove manure that could potentially contain clostridial bacteria can reduce the amount of bacteria in the environment and reduce the likelihood of ingestion. Studies have suggested that washing the mare's udder following foaling to ensure that the teats are clean when the foal suckles can also help prevent infection. Thoroughly disinfecting foaling stalls between use, and having strict isolation protocols between mare and foal pairs is key in reducing the risk of spreading infection and preventing farm outbreaks of clostridial infections.

Another method to decrease the risk of *C. perfringens* infection is to vaccinate the pregnant mare with a *C. perfringens* toxoid at 6 and 3 weeks prior to foaling. The idea is to have antibodies against the *C. perfringens* bacteria present in the colostrum when the foal is born. There is unfortunately no vaccine for *C. difficile* at this time. Although it is tempting to prophylactically treat foals with antibiotics in an effort to prevent clostridial enterocolitis, research has shown that *C. difficile* infections can be caused by administration of antibiotics and some strains of *Clostridium* spp. are showing antibiotic resistance; therefore, **prophylactic antibiotic use is not recommended** to prevent these infections. Consulting your veterinarian to establish preventative measures is highly recommended.

References:

1. C.S. Park, J. Y. Hwang, and G. J. Cho. The first identification and antibiogram of *Clostridium perfringens* type c isolated from soil and the feces of dead foals in South Korea. *Animals*. 2019. 579 (9).
2. I. M. Gohari, S. Unterer, A. E. Whitehead, J. F. Prescott. Netf-producing clostridium perfringens and its associated diseases in dogs and foals. *Journal of Vet. Diagnostic Investigation*. 2020. 32 (2); 230-238.
3. J. S. Weese, H. R. Staempfli, and J. F. Prescott. A prospective study of the roles of clostridium difficile and enterotoxigenic clostridium perfringens in equine diarrhoea. *Equine Vet. J.* 2001. 33 (4); 403-409.
4. K. Gary Magdesian. Neonatal foal diarrhea. *Vet Clin North Am Equine Pract.* 2005. 21 (2); 295-312.
5. L. G. Arroyo, J. S. Weese, and H. R. Staempfli. Experimental clostridium difficile enterocolitis in foals. *J. Vet Intern Med.* 2004. 18; 734-738.
6. P. M. McCue. Clostridium enterotoxemia in foals. *CSU*.
7. S. S. Diab, H. Kinde, J. Moore, M.F. Shahriar, J. Odani, L. Anthenill, G. Songer, F. A. Uzal. Pathology of clostridium perfringens type c enterotoxemia in horses. *Vet. Path.* 2011. 49 (2); 255-263.

Rehab (continued from page 5)

Common indications for laser therapy include osteoarthritis, wounds, soft tissue injuries, and localized pain.³ Studies have reported that lasers provide pain relief as well as have a positive effect on wound healing. Laser treatments are performed multiple times a week.

It is well understood that physical rehabilitation is a valuable and versatile component of equine medicine. It would be rare to find a horse that could not benefit in some way from what it can offer; however, extensive research has not yet been performed in this field. There are very limited numbers of well-designed, blinded, randomized, controlled studies, cohort studies, or systematic reviews on the topic of equine physical rehabilitation.⁷ Many of the specific techniques in equine physical rehabilitation, even some of the most frequently utilized such as those described in this article, are chosen based on "unsubstantiated claims of effectiveness or indications for treatment", as well as clinician experience.⁸ There is an urgent need for well-designed studies in almost all the elements of equine physical rehabilitation so keep this in mind as you incorporate them into any programs for your equine companions.

References

1. Le Jeune, S. et al (2016). Acupuncture and Equine Rehabilitation. *Veterinary Clinics of North America: Equine Practice*, 32, 73-85. doi:10.1016/j.cveq.2015.12.004
2. Phillips, D., & Goldberg, M. E. (n.d.). Introduction to Equine Rehabilitation. Retrieved November 3, 2020, from https://cdn.ymaws.com/www.navta.net/resource/resmgr/media/Equine_Rehab.pdf
3. Adair, S. (2014). Introduction to Equine Rehabilitation Modalities. In *Equine Rehabilitation*. Tennessee: Veterinary Partners Appreciation Conference (V-PAC). Retrieved November 3, 2020, from <http://trace.tennessee.edu/vpac/proceedings2014/largeanimal/11>
4. Kaneps, A. J. (2016). Practical Rehabilitation and Physical Therapy for the General Equine Practitioner. *Veterinary Clinics of North America: Equine Practice*, 32(1), 167-180. doi:10.1016/j.cveq.2015.12.001
5. Beckstett, A. (2014, September 3). *Horse Rehabilitation Exercises from the Ground*. Retrieved November 3, 2020, from <https://thehorse.com>
6. Schlachter, C., & Lewis, C. (2016). Electrophysical Therapies for the Equine Athlete. *Veterinary Clinics of North America: Equine Practice*, 32, 127-147. doi:10.1016/j.cveq.2015.12.011
7. Haussler, K. (2009). Current Status of Integrative Medicine Techniques Used in Equine Practice. *Journal of Equine Veterinary Science*, 29(8), 639-641. doi:10.1016/j.jevs.2009.07.005
8. Haussler, K. K., King, M. R., Peck, K., & Adair, H. S. (2020). The development of safe and effective rehabilitation protocols for horses. *Equine Veterinary Education*. doi:10.1111/eve.13253

Dorsal Metacarpal Disease of Thoroughbreds

By Taylor Baird, DVM Student (Class of 2021) – Edited Dr. Tim Lescun, Large Animal Surgery

Dorsal metacarpal disease (DMD) is one of the most common performance-limiting conditions of racehorses. This disease complex consists of a painful periostitis and potentially stress fractures of the dorsal surface of the third metacarpal bone (MC3) in horses. This injury primarily affects Thoroughbreds but has been seen in Standardbreds and Quarter Horses as well. Clinical signs of DMD include pain with digital palpation and swelling on the dorsal, and sometimes dorsomedial, aspect of MC3 and is seen in mostly 18 to 36 month-old Thoroughbred racehorses.¹ In severe cases, these changes can be accompanied by macroscopic bony enlargements that can change the shape and contour of the bone, giving this disease the nickname “bucked shins.” Studies show incidence as high as 70% in racehorses in the US, making this disease arguably one of the most common causes of lost training days and racing in Thoroughbred racehorses and the subject of much investigation.²

Over the years, racehorses have been asked to run harder and faster, leading to an increased muscle mass and an intensive training schedule at a young age. This intensive regimen at a younger age combined with a heavier horse has led to vulnerabilities in the limbs and reduced ability of MC3 to adapt quickly. When young horses are put into training during this time, their bone is introduced to high levels of stress. According to Wolff’s law, training and racing induces an increase in thickness of the bone in order to withstand the strain placed on it. If repetitive, high-speed, cyclic exercise is introduced before the bone can adapt adequately, damage in the form of microfractures can occur. In response to this type of fatigue damage, excessive periosteal bone growth occurs. At around 2 years of age, MC3 has a larger amount of resorption cavities and incompletely filled secondary osteons than older horses due to the resorption of the primary osteons. This makes for a more porous, less stiff bone that is even more susceptible to microdamage. Greater strain on the bone results in more movement of the dorsal cortex during high-speed exercise. Since primary bone is stronger than remodeled bone, horses with DMD are susceptible to future fracture that could be detrimental to their careers and health.¹

While DMD has a few different manifestations, they all arise from the same cause—intensive training before the horse is skeletally adapted to the training loads. This has been shown in multiple studies demonstrating the increase in bone density of horses undergoing exercise. This greater strain can lead to low cycle fatigue of the bone resulting in bone pain and even fracture. This is seen even more so in the lead limb of racehorses (the left limb in the United States) and is the location where fractures are more likely to occur in DMD.³

Treatment of DMD depends on the severity and chronicity of the disease. For most horses with acute DMD, 5 to 10 days of rest

and NSAIDs are adequate to return them to light training. This training must be gradually increased with constant monitoring of the dorsal surface of MC3. An ease back into training allows MC3 to model according to the stress demands without producing structural damage. For subacute and chronic cases, the amount of rest needed to return to pain-free training is about 110 days.¹ There are several surgical options for treatment of dorsal MC3 fractures that include placement of a neutral unicortical screw in a lag fashion and/or dorsal cortical drilling (osteostixis). A study from California used records of 116 horses with dorsal cortical fractures of MC3 that were repaired with lag screw fixation to show the successful return to racing potential after surgery. In this study, all horses had radiographic resolution of the fracture 60 days after surgery and only 7% of the fractures reoccurred.⁴

Extracorporeal shock wave therapy is another treatment modality available. These shock waves are acoustic pressure gradient waves that are utilized to treat a variety of musculoskeletal diseases in both humans and animals. While the exact mechanism of how shock wave therapy exerts its healing effects on tissues is unknown, pain relief over the treated areas has been documented.⁵ For this reason, it is important not to exercise performance horses with predisposing lesions (like DMD) too soon after the application of shock wave therapy. A study done in New Jersey demonstrated the added benefit of radial shock wave therapy when combined with an appropriate training program in the treatment of DMD. In this study, 45 of 50 horses diagnosed with DMD that was unresponsive to conventional therapy were able to return to racing.⁶

Thankfully the prognosis for DMD is very good. Advances in modern medicine like gait analysis and nuclear medicine have led to more information on DMD, and will hopefully provide more insight into predisposing factors in the future and an ability to prevent the disease in most cases.

References

1. Baxter G, Stashak T. *Lameness of the Extremities. In Adams and Stashak's Lameness in Horses, 6th ed. Baxter, G editor. (2011) Chichester, West Sussex: Wiley-Blackwell.*
2. Norwood G. *The bucked shin complex in Thoroughbreds. Proceedings of the 24th Convention of the American Association of Equine Practice. St. Louis MO, USA; 1978. p. 319-335.*
3. Couch S, Nielsen BD. *A review of dorsal metacarpal disease (bucked shins) in the flat racing horse: prevalence, diagnosis, pathogenesis, and associated factors. J Dairy Vet Anim Res. 2017;5(6):228-236*
4. Jalim SL, McIlwraith CW, Goodman NL, Anderson GA. *“Lag screw fixation of dorsal cortical stress fractures of third metacarpal bone in 116 racehorses.” Equine vet. J. 2010;42(7):586-590.*
5. Bolt DM, Burba DJ, Hubert JD, Pettifer GR, Hosgood GL. *Evaluation of cutaneous analgesia after non-focused extracorporeal shock wave application over the 3rd metacarpal bone in horses. Can J Vet Res. 2004;68(4):288-292.*
6. Palmer SE. *Treatment of dorsal metacarpal disease in the Thoroughbred racehorse with radial extracorporeal shock wave therapy. Proc 48th Annu Conv Am Assoc Equine Pract 2002:318-321*

College of Veterinary Medicine

EQUINE SPORTS MEDICINE CENTER

1248 Lynn Hall

West Lafayette, Indiana 47907-1248

ADDRESS SERVICE REQUESTED

Phone: 765-494-8548

Fax: 765-496-2641

www.vet.purdue.edu/esmc/

EQUINE HEALTH UPDATE

Published by the College of Veterinary Medicine Equine Sports Medicine Center. With generous support of Purdue University's Veterinary Teaching Hospital and the College of Veterinary Medicine Dean's Office.

Please address all correspondence related to this newsletter to the address above.

EDITORIAL BOARD:

Drs. Couétil L., Hawkins J. and Tinkler S.

DESIGN & LAYOUT BY:

Elaine Scott Design

EA/EOU



The Equine Sports Medicine Center

Purdue's Equine Sports Medicine Center is dedicated to the education and support of Indiana horsemen and veterinarians through the study of the equine athlete. The Center offers comprehensive evaluations designed to diagnose and treat the causes of poor performance, to provide performance and fitness assessments, and to improve the rehabilitation of athletic horses. Other integral goals of the Center are to pioneer leading-edge research in the area of equine sports medicine, to provide the highest level of training to future equine veterinarians, and to offer quality continuing education to Indiana veterinarians and horsemen. For more information visit our website:

www.vet.purdue.edu/esmc/



Continuum© by Larry Anderson