

Impact of prophylactic corticosteroids on systemic inflammation after extensive atrial ablation in pigs[†]

Thais Nascimento¹, Fernanda Mota¹, Luis Felipe dos Santos¹, Sérgio de Araujo², Mieko Okada¹, Marcello Franco², Angelo de Paola¹, and Guilherme Fenelon^{1*}

¹Discipline of Cardiology, Paulista School of Medicine, Federal University of São Paulo, Pedro de Toledo 781, 10th Floor (Cardiology), São Paulo, SP 04039-032, Brazil; and

²Department of Pathology, Paulista School of Medicine, Federal University of São Paulo–São Paulo, Rua Botucatu 740, São Paulo, SP 04039-030, Brazil

Received 6 April 2011; accepted after revision 12 July 2011; online publish-ahead-of-print 15 August 2011

Aims

Prophylactic corticosteroids have been reported to attenuate the increase in C-reactive protein (CRP) and the incidence of atrial fibrillation (AF) both after heart surgery and AF ablation. We tested the impact of a single prophylactic corticosteroid dose on ultrasensitive CRP 24 h and 14 days after extensive linear atrial ablation (8 mm or 3.5 irrigated tip) guided by electroanatomical mapping (NavX) in pigs with normal hearts.

Methods and results

Pigs ($n = 19$; 35 kg) were divided into three groups: corticoid ($n = 7$), atrial ablation with administration of 500 mg methylprednisolone intravenous at anaesthetic induction; control ($n = 7$), atrial ablation only; and sham ($n = 5$), surgical procedure without ablation. Troponin and CRP were measured before, 24 h and 14 days after the procedure. After sacrifice, lesions were analysed macroscopically and histologically. Linear lesions were created in the right ($n = 23$) and left ($n = 21$) atrium of 14 animals, with no difference between groups. In all groups there was elevation of troponin and CRP 24 h after ablation, with a return to baseline values after 14 days. However, CRP levels of the control, corticoid, and sham groups were similar at all three time points analysed (baseline $P = 0.52$, 24 h $P = 0.21$, 14 days $P = 0.66$). Histological analysis did not show any difference between corticoid and control groups.

Conclusion

In this model, extensive biatrial RF ablation, *per se*, does not promote systemic inflammation. The use of a prophylactic single corticoid dose before ablation did not prevent systemic inflammation or alter the healing of the lesions.

Keywords

Arrhythmias • Atrial fibrillation • Radiofrequency ablation • Steroids • Inflammation

Introduction

Systemic inflammation seems to be associated with the genesis of atrial arrhythmias, especially atrial fibrillation (AF), but it has not yet been defined as to whether it is arrhythmia that provokes inflammation or vice versa.¹ Some studies have observed elevation of C-reactive protein (CRP) after radiofrequency (RF) ablation of AF and have correlated it with early recurrence of arrhythmia,² suggesting that the extensive tissue damage produced by ablation may be pro-inflammatory, thus generating AF.³ On the other hand, recent studies evaluating inflammatory markers in patients submitted to ablation of atrial flutter and AF have suggested that

atrial tachyarrhythmias are the cause, and not the effect, of inflammation.^{4,5} Since RF ablation has been increasingly employed in the treatment of AF, two questions raised by these controversies have become important: (i) does ablation *per se* trigger systemic inflammation? (ii) If so, is it possible to prevent the latter? In this respect, the prophylactic administration of a single corticoid dose attenuated the increase in CRP and the incidence of AF during the post-operative period of cardiac surgery,^{6,7} which is a condition known to be pro-inflammatory. In addition, the use of a corticoid on the first 3 days after ablation reduced the elevation of inflammatory markers and the early or late recurrence of AF.⁸ On the basis of these observations, we formulated the hypothesis that the

[†] Presented in part at the Heart Rhythm Society Scientific Sessions, San Francisco 4–7 May 2011.

* Corresponding author. Tel: +55 11 50844829; fax: +55 11 50844829. Email: guilhermefenelon@uol.com.br

Published on behalf of the European Society of Cardiology. All rights reserved. © The Author 2011. For permissions please email: journals.permissions@oup.com.

prophylactic administration of a corticosteroid would attenuate the systemic inflammation induced by ablation.

The objective of the present study was to test the impact of a prophylactic corticosteroid on ultrasensitive CRP before, and 24 h and 14 days after extensive linear atrial ablation guided by electroanatomical mapping in pigs with normal hearts. In addition, we assessed the effects of the drug on the macroscopic and histopathological aspects of the lesions. Finally, we studied the behaviour of CRP in the presence of surgical stress alone (sham controls) in order to determine whether RF-induced lesions *per se* provoke systemic inflammation.

Methods

The study was approved by the Ethics Committee of the Federal University of São Paulo and was conducted according to institutional norms.

Sample

Nineteen young adult male pigs of the Pernalan breed (3 months of age) weighing (35.4 ± 3.23 kg) were quarantined under veterinary surveillance to guarantee their health status.

Experimental preparation

After an 8–12 h fast, the animals were pre-medicated with acepromazine [0.2 mg/kg intramuscular (im)] and midazolam (0.4 mg/kg im) and anaesthetized 15 min later with propofol (1–2 mg/kg intravenous (iv) followed by continuous infusion of 1–4 mg/kg/h). The animals were then intubated and maintained on artificial ventilation with the amount of oxygen necessary to maintain adequate saturation (>90%), under electrocardiographic monitoring and pulse oximetry. Body temperature was maintained at $\sim 37^\circ\text{C}$ with a heating blanket. After shaving and antisepsis, the patches of the EnSite NavX 8.01 system (St Jude Medical, St Paul, MN, USA) were applied, in addition to an indifferent plate electrode. Under sterile surgical conditions, the left (11Fr) and right (11Fr) femoral veins and the right jugular vein (7Fr) were dissected and cannulated and the catheters of the intracardiac echocardiogram (Acunav Acuson 10Fr), the femoral sheath (SL1-St Jude Medical) and the needle (BRK, St Jude Medical) for transseptal puncture were introduced under fluoroscopic guidance, and a diagnostic quadripolar catheter (St Jude Medical) was placed in the coronary sinus. The local electrograms and the ECG were filtered (30–500 Hz) by the TEB SP32 polygraph (Tecnologia Eletrônica Brasileira, São Paulo, Brazil). After transseptal puncture was guided by the intracardiac echocardiogram the animals received 5000 IU of non-fractionated heparin IV (Liquemine® IV).

Electroanatomical mapping

Atrial geometry was constructed in all pigs subjected to ablation using the electroanatomical mapping system EnSite NavX 8.01 (St Jude Medical, St Paul, MN, USA), with the quadripolar catheter positioned in the coronary sinus being used as the anatomical reference electrode. Impedance calibration and compensation of respiratory movements were always performed. The three-dimensional geometry of the cavities was obtained in sinus rhythm using the distal electrode pair of the deflectable 07Fr ablation catheter.

Ablation procedure

Under fluoroscopy and with the aid of the virtual map, a linear lesion was initially created inside the right pulmonary vein from the distal

portion (± 2 cm) to the ostium. Venous angiography was performed before and after this procedure to determine the patency of the vein. Next, 1–2 linear lesions were created in each atrium: from the appendage to the right pulmonary vein and from the roof to the right pulmonary vein in the left atrium, and from the superior vena cava to the inferior vena cava through the lateral surface of the atrium and from the appendage to the superior vena cava in the right atrium. Each unipolar RF application (Stockert generator, Biosense Webster Inc., Diamond Bar, CA, USA) lasted 90 s, with the catheter being dragged along the line every 15–20 s simultaneously to the acquisition of the marks on the virtual map. However, no electrophysiological manoeuvres were performed to confirm the line of block. Ablation was performed with 7Fr catheters either with an 8 mm tip (Biosense Webster) at a maximum power of 70 W and under controlled temperature at 60°C , or with a 3.5 mm irrigated tip (Irvine Biomedical, Irvine, CA, USA), at a maximum power of 50 W, a temperature of 50°C and with continuous irrigation of 17 mL/min during the application. The power (Watts), impedance (Ω), and temperature ($^\circ\text{C}$) of the catheter tip were monitored during each application and the mean value was recorded for analysis. The application was interrupted if a pop occurred and the catheter was checked for the presence of clots. The animals that presented arrhythmias during the procedure, with ventricular fibrillation being the most common since pigs are highly susceptible to this arrhythmia, were subjected to transthoracic defibrillation with the plates positioned transversely. At the end of the procedure, the catheters were removed, the vessels were ligated and the wounds sutured. The procedures were performed by the same operator under sterile conditions, with no need for prophylactic antibiotics. Also, no anticoagulants or antiplatelet aggregating agents were administered.

Study groups

The animals subjected to ablation were divided into two groups: control ($n = 7$) which did not receive any drugs and corticoid ($n = 7$), which received 500 mg methylprednisolone iv in bolus during anaesthesia induction. In both groups, five animals were ablated with an 8 mm catheter and two with an irrigated catheter. A sham group ($n = 5$) was also studied, being subjected to the surgical procedure (dissection of the veins with introduction of the catheters and transseptal puncture with angiography of the pulmonary vein), but without RF application. All pigs were followed up for 14 days under veterinary care.

C-reactive protein and troponin

Blood samples were collected during anaesthesia induction, 24 h and 14 days after baseline collection and centrifuged, and plasma was stored in a serum bank at -20°C . Troponin (Accu Tni Access—Beckman Coulter) and CRP (CRP latex—Olympus) was determined at these three time points in separate samples. All measurements were confirmed with two different kits.

Macroscopic analysis

The animals were returned to the laboratory 14 days after the procedure, weighed, and sacrificed with a lethal KCl injection under general anaesthesia. The heart was carefully removed and the ablation lines were macroscopically identified, correlated with the applications to the cardiac cavities, measured in width, length, and depth with a millimetre ruler on the epicardial and endocardial surfaces, and then documented with digital photography.

Histological analysis

The linear lesions were sliced on various sequential transverse histological sections so that they would be fully covered. The slides were stained with haematoxylin–eosin (H&E) and Masson trichrome and qualitatively analysed by a pathologist who was blind to the study groups. Special attention was paid to the healing characteristics of the lesions such as transmural, continuity, density of fibrosis, and inflammation.

Statistical analysis

The continuous variables were analysed descriptively as mean and standard deviation. The medians and respective interquartile intervals were calculated for the measurements of troponin and CRP. The Friedman test was used to compare the median troponin and CRP values within each group, followed by the Wilcoxon test to identify which strata differed from one another, considering the 'P' value obtained by Bonferroni correction as the level of significance. The median values for troponin and CRP were compared between groups using the Kruskal–Wallis test followed by the Mann–Whitney test to identify which groups differed from one another, considering the 'P' value obtained by Bonferroni correction as the level of significance. An alpha (α) value of 5% or less was considered to be statistically significant.

Results

Radiofrequency ablation

With the aid of a virtual map, 23 linear lesions were created in the right atrium and 21 in the left atrium of 14 animals in the corticoid and control groups. The mean power, temperature, and impedance of application were 56 W, 54°C, and 231 Ω for the 8 mm catheter and 39 W, 37°C, and 94 Ω for the irrigated catheter, respectively, with no differences between groups. Table 1 lists the amount of contrast given, the times of RF application and the arrhythmias observed in the animals, parameters that were similar for the two groups. The incidence of the pop phenomenon was also similar, with two episodes per group. No significant stenosis (>40%) or occlusion of the ablated pulmonary vein was observed. Twelve defibrillations were needed during the procedures due to episodes of ventricular fibrillation and four cardioversions were performed due to episodes of atrial tachycardia in

the animals subjected to ablation, with equal distribution between groups. One death per group occurred during ablation: one due to cardiac tamponade after a pop and the other due to haemorrhagic complications during vascular dissection. The two animals were excluded from the study. No intercurrent was observed in the sham group.

Follow-up

The 19 animals completed the 14-day follow-up without intercurrents and weight gain did not differ between groups (Table 1).

Troponin and C-reactive protein

Troponin was significantly increased in the three groups after 24 h ($P = 0.003$), although much less so in the sham group (Figure 1), returning to baseline values after 14 days (Figure 2). There was no difference between the control and corticoid groups. There was no difference in CRP values between the control, corticoid, and sham groups (Figure 1) at any of the three time points investigated (baseline, 14 h and 14 days) elevation of CRP occurred in all groups 24 h after ablation, with a return to baseline values after 14 days (Figure 2).

Macroscopic analysis

All of the 23 linear lesions created in the right atrium and the 21 lesions created in the left atrium (100%) were identified on both the epicardial and the endocardial surfaces. Macroscopic inspection revealed extensive and pale lesions measuring 3.0–5.5 cm in length and 1.2–2.0 cm in width. They apparently were transmural (the atrial wall thickness ranged from 0.5 to 1.2 cm) and continuous and did not differ between groups. The lesions created with the irrigated catheter were more difficult to visualize macroscopically since they were paler and had less defined margins, although they did not differ in dimensions or transmural. It is interesting to note that the lesions were anatomically correlated with the location provided by the Ensite NavX 8.01 System (Figure 3). The groups did not differ regarding the macroscopic aspect of the lesions, including those located inside the pulmonary vein.

Table 1 Biometric data of the pigs, biophysical parameters of radiofrequency applications and arrhythmias during ablation

Group	Weight (kg)		Contrast used (mL)	RF Ablation			Arrhythmias/number of shocks
	Initial	Final		Atrium	Time (s)	Linear lesions (n)	
Sham	33.48 ± 3.41	38.40 ± 2.88	25.60 ± 15.06	Right	0	–	–
				Left	0	–	–
Control	35.21 ± 3.16	40.86 ± 5.37	29.43 ± 11.87	Right	508.43 ± 57.76	13	AT/3
				Left	481.43 ± 62.59	11	VF/4
Corticoid	36.94 ± 2.76	37.36 ± 4.78	21.71 ± 11.59	Right	526.86 ± 47.64	10	AT/1
				Left	515.86 ± 19.28	10	VF/8

AT, atrial tachycardia; VF, ventricular fibrillation.

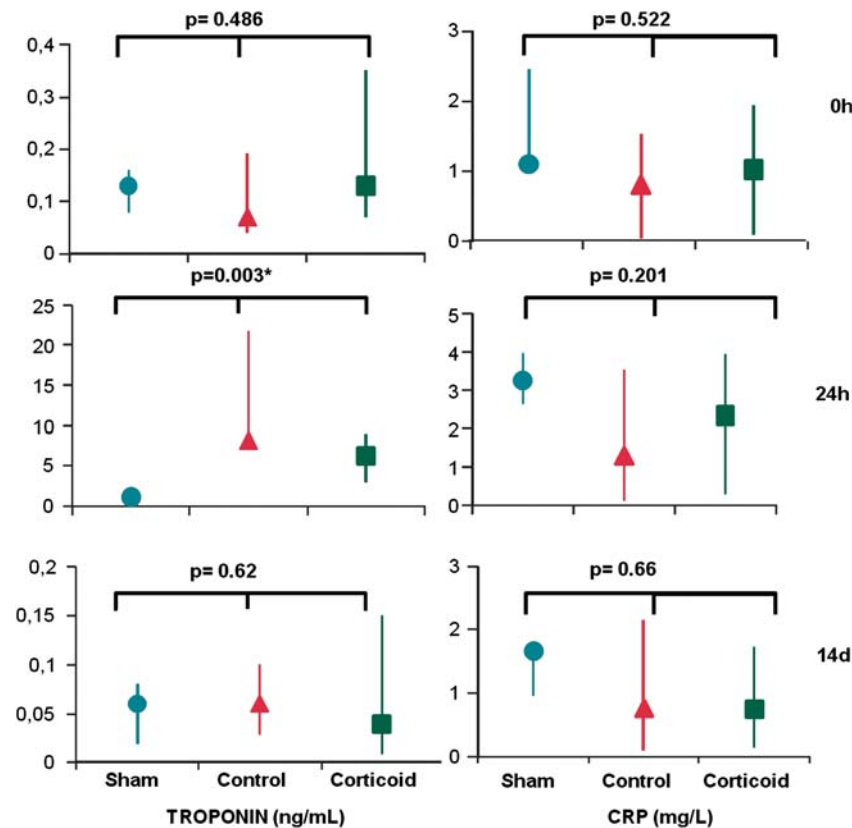


Figure 1 Analysis from median and interquartile ranges of TROPONIN (left) and C-reactive protein (CRP, right) between groups (intergroup analysis) at baseline (0 h), 24 h (24 h), and 14 days (14 d) after ablation. C-reactive protein levels of the control, corticoid, and sham groups were similar at all three time points analysed. Troponin levels for control and corticoid groups were similar and significantly higher than sham controls at 24 h. * $P < 0.05$ was considered statistically significant.

Histological analysis

The lesion lines were cut transversely into consecutive sections and their transmuralities were confirmed (Figure 4). The qualitative analysis was quite consistent: there was coagulative necrosis with necrotic muscle being replaced with newly formed fibrosis. Granulation tissue was present in some lesions, in addition to calcification, recent thrombus and lymphocytic infiltration. The borders of the lesions were characterized by necrotic tissue with an inflammatory cellular infiltration rich in macrophages and lymphoplasmacytic cells and also various degrees of fibrosis and neovascularization (Figure 5). Interestingly, there were no histological differences between the control and corticoid groups.

Discussion

Main findings

In this model of extensive atrial ablation in pigs we demonstrated that: (i) the elevation of CRP after the procedure was not related to ablation *per se*, since it was similar in the corticoid, control, and sham groups; (ii) the prophylactic corticoid administered as a single

dose did not affect the inflammatory process occurring after the procedure or the healing of the lesions.

Comparison with other studies

Atrial fibrillation is the most frequent sustained clinical arrhythmia but its aetiology has not been fully elucidated. After the first evidence of tissue inflammation documented in atrial tissue biopsies from patients with lone AF,⁹ to date the role of the inflammatory process in the genesis and maintenance of arrhythmia has not been defined, especially regarding whether it is the arrhythmia that provokes inflammation or vice versa. Some studies have correlated inflammatory markers with arrhythmia. The documented reduction of these markers [CRP and interleukin (IL)-6] after the return to sinus rhythm both by a strategy of cardioversion¹⁰ or by ablation,³ suggests that the presence of arrhythmia perpetuates the inflammation. Marcus *et al.*⁴ evaluated the behaviour of CRP and IL-6 after ablation of atrial flutter and observed that the absence of arrhythmia was correlated with a reduction of these markers, and therefore considered the arrhythmia, and not ablation, to be responsible for the inflammation. In 2010, the same group published⁵ a study comparing the measurement of CRP during periods of AF and of sinus rhythm, supporting the notion

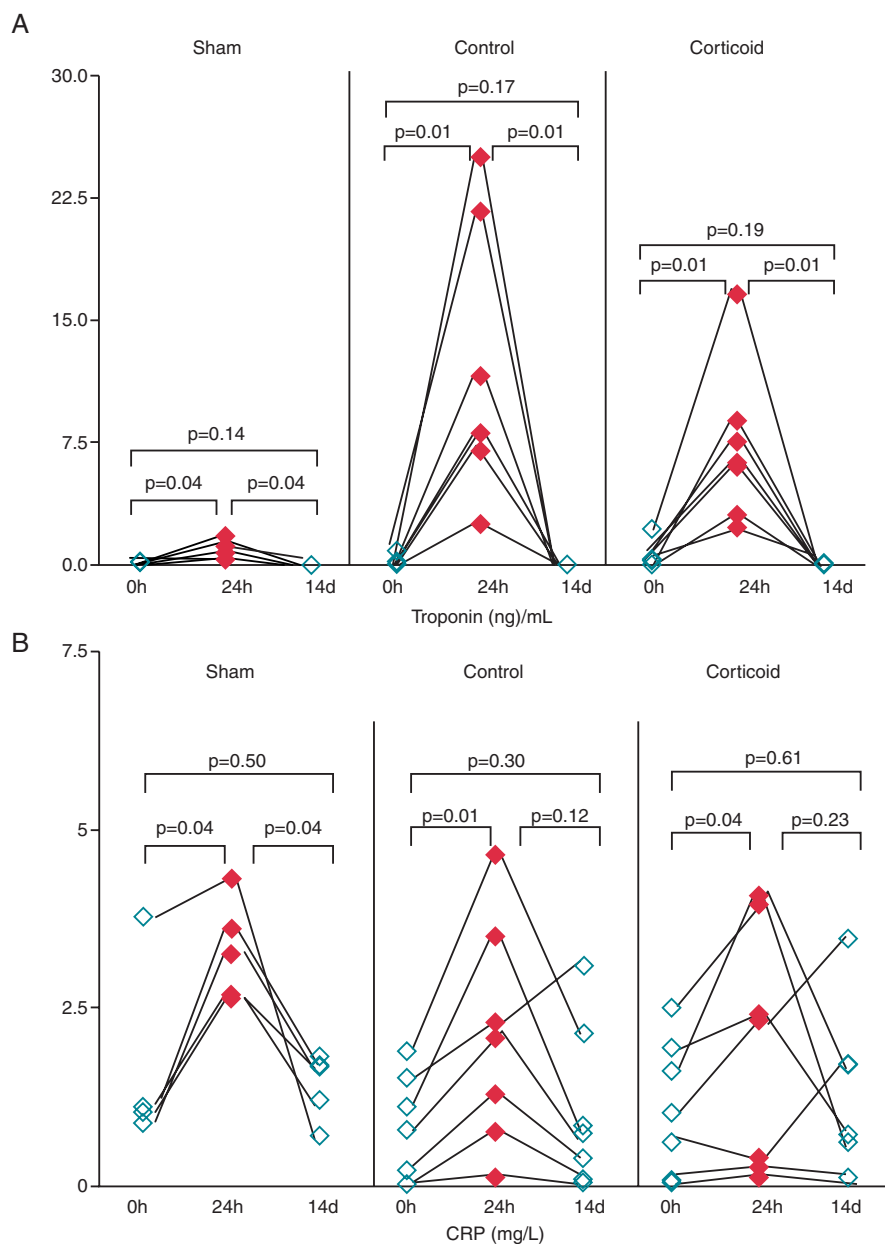


Figure 2 Individual change in (A) Troponin and (B) C-reactive protein (CRP), in the three groups (intra-group analysis) at baseline (0 h), 24 h (24 h), and 14 days (14 d) after ablation. In all groups, there was a significant elevation of troponin and C-reactive protein 24 h after ablation, with a return to baseline values after 14 days.

that the increased levels of the markers were associated with the presence of arrhythmia and were not related to a previous history of arrhythmia. McCabe *et al.*,³ in turn, reported CRP elevation after a mean period of 49 days since AF ablation and suggested that the inflammation generated by ablation was responsible for the recurrence of arrhythmia. However, in the cited study the CRP curve for patients with no recurrence of AF was similar to that for the patients subjected to ablation of supraventricular tachycardia, so that CRP elevation was fundamentally observed in patients in whom AF recurred, leaving unresolved the question of whether AF or ablation was responsible for inflammation.

The present findings suggest that the extensive tissue damage due to ablation was not responsible, *per se*, for systemic inflammation. The elevation of CRP was related to surgical stress, including general anaesthesia, mechanical ventilation, animal manipulation and instrumentation, vein dissection, transeptal puncture, and angiography of the pulmonary vein. Our data were obtained in young healthy animals with no arrhythmias, so that the behaviour of CRP regarding the procedure could be assessed without confounding factors known to be related to inflammation, such as systemic arterial hypertension, diabetes, dyslipidemias, obesity, and mainly AF. In addition, the impact of surgical stress alone

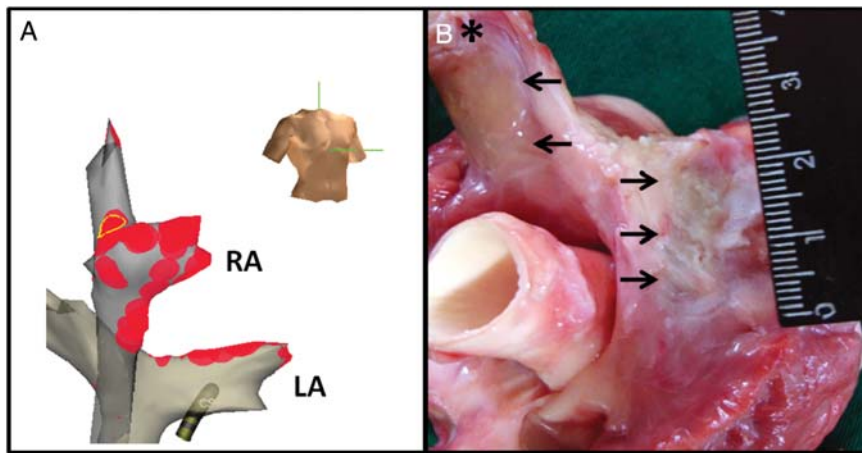


Figure 3 Gross pathological and electroanatomical mapping findings of extensive linear radiofrequency lesions in a pig. (A) Right anterior oblique view of the NavX map of the left atrium (LA) and right atrium (RA) showing the location of radiofrequency applications (red spots). The coronary sinus (CS) reference catheter is also shown. (B) Epicardial surface of the heart displaying continuous linear lesions (arrows) on the left atrium roof and in the pulmonary vein (*), denoting transmural lesions. The lesions were anatomically correlated with the location provided by the NavX system.

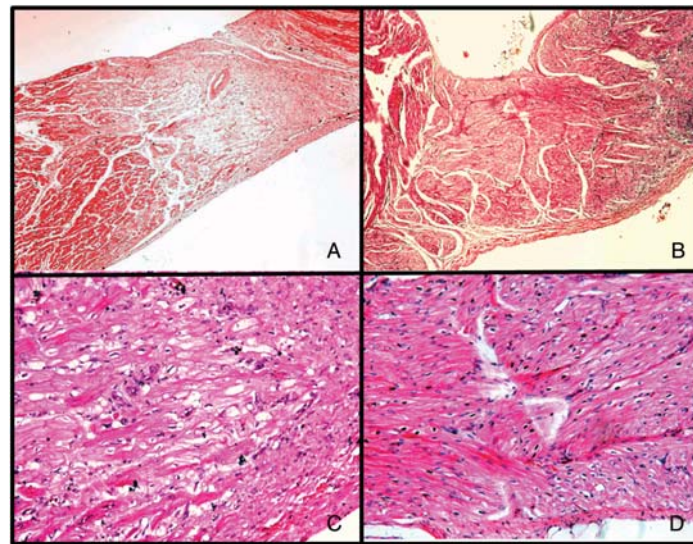


Figure 4 Comparison of histological findings between control (A and C) and corticoid (B and D) groups. (A) and (B) illustrate atrial transmural lesions (H&E, 4 \times) and (C) and (D) illustrate the pattern of inflammatory cells and fibrous tissue (H&E, 10 \times). Note that there are no appreciable differences between the groups. See text for details.

was assessed in the sham group, a fact that is seldom possible in clinical studies. Our results cannot be attributed to methodological discrepancies of the model. The linear lesions were created under the guidance of electroanatomical mapping, with the application of ± 500 s of RF per atrium, using even higher biophysical parameters of application than those used in clinical practice (a power of 70 W with an 8 mm catheter and a power of up to 50 W with the irrigated catheter). It should also be pointed out that the size

and weight of the animals are smaller than those of adult men. The extent of myocardial damage was confirmed by the substantial elevation of troponin and also by pathological analysis, which consistently revealed long and transmural lesions. Thus, the protocol was designed in such a way as to guarantee that the extent of ablation would be sufficient to reproduce the increase of the inflammatory marker related to the procedure. Indeed there was a significant increase in CRP in the groups subjected to ablation.

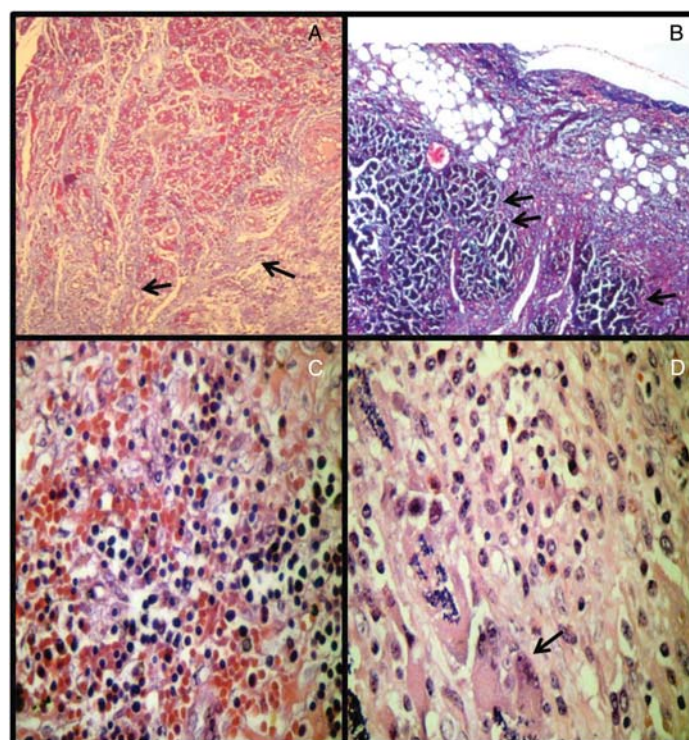


Figure 5 Histological findings of radiofrequency ablation lesions. (A) (Masson, 10 \times) shows interstitial fibrosis surrounding myocardial tissue (arrows). (B) (Masson, 10 \times) the epicardial surface of the lesion shows fibrosis with modest lymphocytic infiltrate and areas of necrosis (arrows). (C) (control, H&E, 20 \times) and (D) (corticoid, H&E, 40 \times) illustrate the local inflammatory response characterized by cellular infiltration rich in lymphoplasmacytic cells and macrophages (giant cell, arrow). There were no histological differences between the control and corticoid groups.

C-reactive protein determination with the human kit used in the present study has been previously validated and has proved to be accurate for pigs.^{11,12} It was noteworthy that there was no difference in weight between the animals of the three groups, and parameters such as RF application, troponin levels, and extent of the lesions determined by pathological analysis did not differ between control and treated animals. Thus, the similar increase in CRP in the sham, control, and corticoid groups suggests that ablation, *per se*, does not play a central role in the systemic inflammation occurring after the procedure, since the inflammatory response to surgical stress alone would be highly unlikely to be so intense as to mask the pro-inflammatory effects of ablation.

The use of a prophylactic corticoid prevented the post-operative occurrence of AF after cardiac surgery.^{6,7} Within this context of extensive cell damage associated with extracorporeal circulation, the corticoids act by improving the myocardial cell integrity, reducing the expression of adhesion molecules, the activation of complement and the release of cytokines. A recent study evaluated the effect of the use of small corticoid doses (2 mg/kg hydrocortisone iv at the time of ablation, followed by 0.5 mg/kg/day oral prednisone for 3 days) on AF recurrence after RF ablation.⁸ Body temperature, white cell count and CRP were measured. A detailed analysis of this study indicates that the

effect of the corticoid was demonstrated in the group in which AF recurred immediately after ablation (within a period of 3 days), with no effect on the patients with no recurrence of arrhythmia. The present results agree with these observations. As also observed in the present study, in which the animals had no arrhythmias, the CRP values for patients with no recurrence of AF were similar for the corticoid and placebo groups. The reasons for the lack of an effect of corticoids on CRP levels in these patients, as well as in the present study, are unclear. However, we may speculate that the anti-inflammatory action of the drug may be more evident in situations of expressive systemic inflammation as observed in patients with comorbidities and/or AF.

Clinical implications

Radiofrequency ablation is being increasingly used for the treatment of AF and some studies³ have suggested that the early recurrence of arrhythmia may be related to the inflammation promoted by the extensive tissue damage produced by ablation. The present results suggest that extensive atrial ablation, *per se*, does not provoke a relevant systemic inflammatory response, in agreement with previous studies⁴ indicating that ablation is not responsible for early AF recurrence.

It is well known that the chronic use of corticoids is associated with a delayed healing process which may cause thinning of the tissue, favouring perforations.¹³ Furthermore, we have shown that treatment with hydrocortisone (10 mg/kg iv) immediately after RF ablation and prednisone [1 mg/kg po (by mouth)] for 29 days modulates late (8 months) fibrotic proliferation in infant pigs. In this model, ventricular lesions present marked late growth and invasion of normal muscle by fibrous trabeculae (late extension). Corticosteroids did not prevent the late growth of the lesions but attenuated the late extension and fibrosis density in the scar, turning it more fibroadipose.¹⁴ However, the use of short-term (up to 3 days) prophylactic corticoids in patients submitted to AF ablation has proved to be safe.⁸ Although obtained with a different therapeutic regimen, our present findings support the safety of this treatment by demonstrating that there were no histological differences between the corticoid group and the control, thus suggesting that prophylactic corticoid administered as a single dose does not impact on lesion healing. Nevertheless, the data presented provide no support for the routine use of prophylactic corticoids in patients undergoing AF ablation.

Limitations

The study was conducted on healthy pigs with a normal heart and without arrhythmias and therefore the results cannot be directly extrapolated to humans with AF. Despite the limited sample, as frequently seen with large animal models, the results were consistent in all groups. Since the corticoid dose was arbitrary, the present findings cannot be applied to other types of corticosteroids or therapeutic regimens. Other inflammatory markers such as IL-6 were not determined, but it is unlikely that IL-6 would induce responses differing from those to ultrasensitive CRP. C-reactive protein was measured 24 h and 14 days after ablation. Although improbable, it is possible that the peak of the inflammatory process occurred 30–72 h after ablation. Since pigs very easily develop ventricular fibrillation, no RF was applied inside the coronary sinus. Although the duration of RF application (16 min) may not have been sufficiently long to generate inflammation, ablation was quite significant for the size of the pigs, generating lesions comparable to those occurring in human procedures. Finally, although equally distributed between control and corticoid groups, the 12 defibrillations and 4 cardioversions needed during the procedures due to episodes of ventricular fibrillation and atrial tachycardia might have been a significant confounding factor, as there is considerable evidence that cardioversion increases inflammatory markers.¹⁵

Conclusions

In this model of extensive atrial ablation in pigs, the tissue injury induced by RF, *per se*, is not responsible for the systemic

inflammation occurring after the procedure. The prophylactic use of a single corticoid dose before ablation did not prevent systemic inflammation and did not change the healing of the lesions.

Conflict of interest: none declared.

Funding

Supported by research grants from Fundação de Amparo à Pesquisa de Estado de São Paulo—FAPESP (T.N. and G.F.).

References

1. Chung MK, Martin DO, Sprecher D, Wazni O, Kanderian A, Carnes CA *et al*. C-reactive protein in patients with atrial arrhythmias: inflammatory mechanisms and persistence of atrial fibrillation. *Circulation* 2001;**104**:2886–91.
2. Koyama T, Sekiguchi Y, Tada H, Arimoto T, Yamasaki H, Kuroki K *et al*. Comparison of characteristics and significance of immediate versus early versus no recurrence of atrial fibrillation after catheter ablation. *Am J Cardiol* 2009;**103**:1249–54.
3. McCabe JM, Smith LM, Tseng ZH, Badhwar N, Lee BK, Lee RJ *et al*. Protracted CRP elevation after atrial fibrillation ablation. *Pacing Clin Electrophysiol* 2008;**31**:1146–51.
4. Marcus GM, Smith LM, Glidden DV, Wilson E, McCabe J, Whiteman D *et al*. Markers of inflammation before and after curative ablation of atrial flutter. *Heart Rhythm* 2008;**5**:215–21.
5. Marcus GM, Smith LM, Ordovas K, Scheinman MM, Kim AM, Badhwar N *et al*. Intra and extracardiac markers of inflammation during atrial fibrillation. *Heart Rhythm* 2010;**7**:149–54.
6. Marik P, Fromm R. The efficacy and dosage effect of corticosteroids for the prevention of atrial fibrillation after cardiac surgery: A systematic review. *J Crit Care* 2009;**24**:458–63.
7. Ho KM, Tan JA. Benefits and risks of corticosteroid prophylaxis in adult cardiac surgery. A dose response meta-analysis. *Circulation* 2009;**119**:1853–66.
8. Koyama T, Tada H, Sekiguchi Y, Arimoto T, Hiamasaki H, Kuroki K *et al*. Prevention of atrial fibrillation recurrence with corticosteroids after radiofrequency catheter ablation. *J Am Coll Cardiol* 2010;**56**:1463–72.
9. Frustaci A, Chimenti C, Bellocci F, Morgante E, Russo MA, Maseri A. Histological substrate of atrial biopsies in patients with Lone atrial fibrillation. *Circulation* 1997;**96**:1180–4.
10. Kellergis EM, Manios EG, Kanoupakis EM, Mavrakis HE, Kolyvaki SG, Lyrarakis GM. The role of post-cardioversion time course of hs-CRP levels in clarifying the relationship between inflammation and persistence of atrial fibrillation. *Heart* 2008;**94**:200–4.
11. Tecles F, Fuentes P, Subiela SM, Parra MD, Munoz A, Ceron JJ. Analytical validation of commercially available methods for acute phase proteins quantification in pigs. *Res Vet Sci* 2007;**83**:133–9.
12. Saco Y, Fraile L, Giménez M, Canalias F, Bassols A. Validation of an immunoturbidimetric method for determination of porcine serum C-reactive protein. *Res Vet Sci* 2010;**89**:159–62.
13. Fenelon G, Franco M, Mora O, Katchburian E, Paola AAV. Combined therapy with steroids and antioxidants prevents ultrastructural damage surrounding chronic radiofrequency lesion. *Pacing Clin Electrophysiol* 2004;**27**:65–72.
14. Arfelli E, de Araujo S, Okada M, Nascimento T, dos Santos LF, Franco M *et al*. Impact of corticosteroids on late growth of radiofrequency lesions in infant pigs: histopathological and electroanatomical findings. *Europace* 2011;**13**:121–8.
15. Andersson J, Almroth H, Höglund N, Jensen S, Tornvall P, Englund A *et al*. Markers of fibrinolysis as predictors for maintenance of sinus rhythm after electrical cardioversion. *Thromb Res* 2011;**127**:189–92.